



Original Article

Vertical bracket position and occlusal plane angle affected the perception of smile esthetics

Nadda Manoosin, D.D.S.¹Paiboon Techalertpaisarn, D.D.S., Ph.D.²¹Graduate student, Department of Orthodontics, Faculty of Dentistry, Chulalongkorn University, Bangkok, Thailand²Associate Professor, Department of Orthodontics, Faculty of Dentistry, Chulalongkorn University, Bangkok, Thailand

Abstract

Background/objectives To evaluate the attractiveness of smile arcs obtained by different vertical bracket positions and occlusal plane angles (OPAs).

Materials and methods Three dental models represented tooth position after leveling with three bracket positions: a conventional bracket position (Con) according to a guideline based on tooth measurement, and bracket positions resulted in extruding (Ext) or intruding (Int) the maxillary incisors. Photographs of the three models were taken at OPAs of 5, 10, and 15° to the true horizontal. The photographs were digitally morphed onto a posed female smile. Nine smile arc photographs were obtained and assessed by a group of orthodontists, dentists, and laypeople.

Results At an average OPA (10°), the Con10 image received a significantly higher esthetic score compared with the Ext10 and Int10 images. The Ext group smile attractiveness significantly decreased from an OPA of 5° (Ext5 image) to 10° (Ext10 image), while the attractiveness of the Int group significantly increased with increasing OPAs.

Conclusions Vertical bracket position and OPA affected smile arc esthetic perception. At an average OPA, the smile arc obtained by bracket position based on tooth measurement resulted in the most attractive smile arc compared with that obtained by bracket positions resulted in extruding or intruding the maxillary incisors. Extruding the maxillary incisors may be beneficial to those with a low OPA, while intruding the maxillary incisors may be done in patients with a high OPA without showing a flat or reversed smile arc.

(CU Dent J. 2017;40:51–62)

Key words: Bracket positioning; Dental esthetics; Occlusal plane; Orthodontic brackets; Smile

Correspondence: Paiboon Techalertpaisarn, paiboon.t@chula.ac.th

Introduction

An esthetically pleasing smile is frequently requested by people seeking orthodontic treatment. Because a smile is framed by soft tissue, an attractive smile is also determined by a harmonious relationship between the lips and teeth. Therefore, the relationship of the curvature of the incisal edges of the maxillary incisors and canines to that of the lower lip in a posed smile, the smile arc, should be considered in treatment planning (Sarver, 2001).

The ideal smile arc has a maxillary incisal edge curvature parallel to that of the lower lip when smiling; the term consonant describes this parallel relationship. A non-consonant smile arc is characterized by either a flat or reversed maxillary incisal curvature relative to that of the lower lip (Sarver, 2001).

When using a straight-wire technique, the vertical position of the teeth is determined by the vertical bracket position, which affects the smile arc. Sarver suggested that normal orthodontic alignment of the maxillary and mandibular arches may result in a loss of curvature of the maxillary incisors relative to the lower lip curvature (Sarver, 2001). In patients with a gummy smile, maxillary incisor intrusion may improve the gingival display; however, this may result in smile arc flattening. Also, preventing of a deep bite during anterior teeth retraction by intruding the maxillary incisors (Hilgers and Farzin-Nia, 1992) may lead to a flat smile arc. Ackerman et al. reported flattening of the smile arc in approximately 33% of orthodontic treated patients, which was six-fold higher compared with the untreated group (Ackerman et al., 1998).

When considering smile esthetics, however, some recommendations argue against the conventional bracket position and intruding the maxillary incisors. A set formula for bracket position based on tooth measurement compromises the curvature of the maxillary incisal edges, and is not suitable for maximum esthetics (Sarver, 2001). Sabri stated that in bracket positioning, the same level

should not be used for all patients to achieve optimal smile arc esthetics (Sabri, 2005). Some orthodontists prefer the smile arc protection strategy, which suggests clinicians should place brackets on maxillary anterior teeth relatively more gingivally than is common, to accentuate the curvature of maxillary incisal edges and obtain an ideal smile (Pitts, 2009). This may be true if the smile is observed parallel to the occlusal plane. However, this strategy has not been evaluated scientifically to determine if it achieves its stated goal with the human morphology and anatomy that have various antero-posterior occlusal plane angles (OPAs) (Downs, 1949).

This study evaluated the attractiveness of smile arcs obtained by different vertical bracket positions and OPAs. Three bracket positions were tested: conventional bracket position based on tooth measurement, and bracket positions resulted in extruding or intruding the maxillary incisors. The null hypothesis tested was that the attractiveness of smile arcs obtained by different vertical bracket positions and OPAs were not different.

Materials and methods

The study protocol was approved by the Human Research Ethics Committee. This study was conducted in three phases (Figure 1). Prior to Phase 1, a photograph of a posed female smile considered to be an esthetic smile (well-aligned teeth, a Class I incisor relationship, 1 mm gingival display, central incisor gingival lines matching the canines with the laterals' line 0.5 mm below) was obtained by taking a photograph of the lower one-third of the face using a digital camera (Canon EOS 50D, Tokyo, Japan).

Phase 1: Simulation of tooth position at different bracket positions and OPAs

1. Horizontal lines (bracket slot positions) were drawn on the labial and buccal surfaces of 12 artificial maxillary teeth (New Ace, Yamahashi Dental

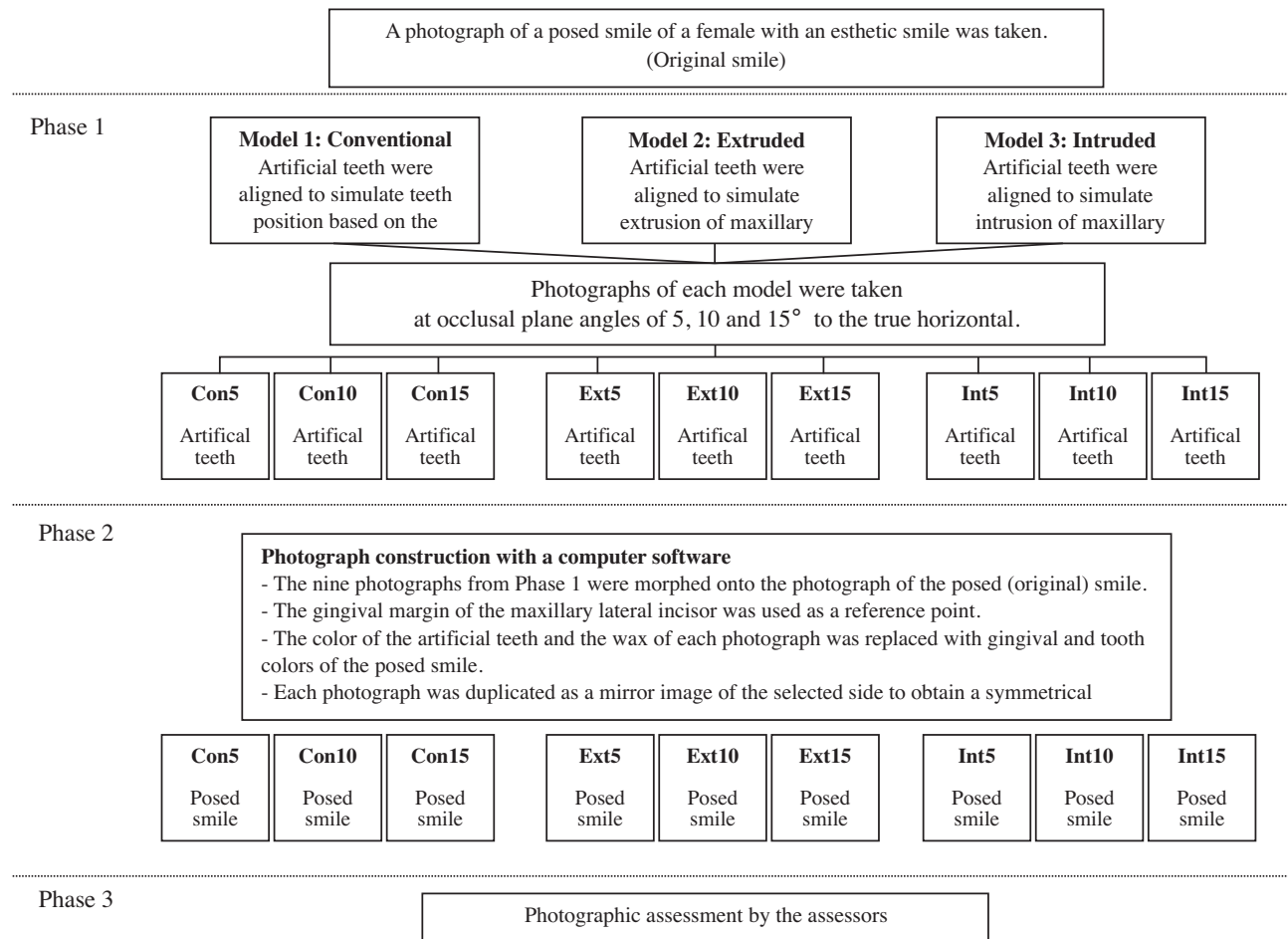


Figure 1: Schematic diagram of smile construction.

Products, NJ) based on tooth measurement per the MBT Versatile+ Appliance Bracket Placement Guide (Unitek, 2015), using a Boone gauge (Ormco, Orange, CA). The guideline was used for model 1; models 2 and 3 had vertical position alterations on the central and lateral incisors, as described below

Model 1 (Conventional group: Con) Based on the placement guideline (Unitek, 2015), the lines were drawn 5 mm from the incisal edges of the maxillary central incisors and canines and 4.5 mm from the incisal edges of the lateral incisors.

Model 2 (Extruded group: Ext) For the maxillary central and lateral incisors, the lines were marked 1 and 0.5 mm, respectively, more gingivally than those of the guideline to simulate maxillary incisors extrusion and accentuate the smile arc.

Model 3 (Intruded group: Int) The lines on the maxillary central and lateral incisors were drawn 1 mm more incisally than the guideline to simulate a 1-mm maxillary incisor intrusion.

2. For each model, the upper and lower artificial teeth were aligned on occlusal rims mounted on an articulator (Hanau, Buffalo, New York, NY) to obtain a molar and canine Class I relationship, normal overjet and overbite. For the upper arch, the vertical positions of the teeth were determined by leveling the horizontal lines on each tooth into a straight line (Figure 2). The inter-canine width and clinical crown length of the same tooth on each model were controlled to be equal.

3. Each model was positioned to have the occlusal plane parallel to the true horizontal. A digital camera on an adjustable tripod (Velbon Victory 450,

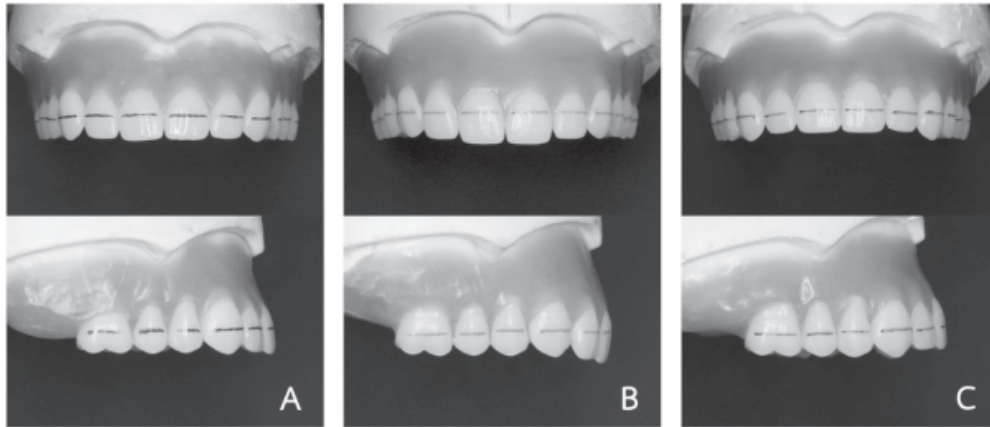


Figure 2: Frontal and lateral view of different bracket positions at an OPA of 0° A) Conventional group, B) Extruded group, and C) Intruded group.

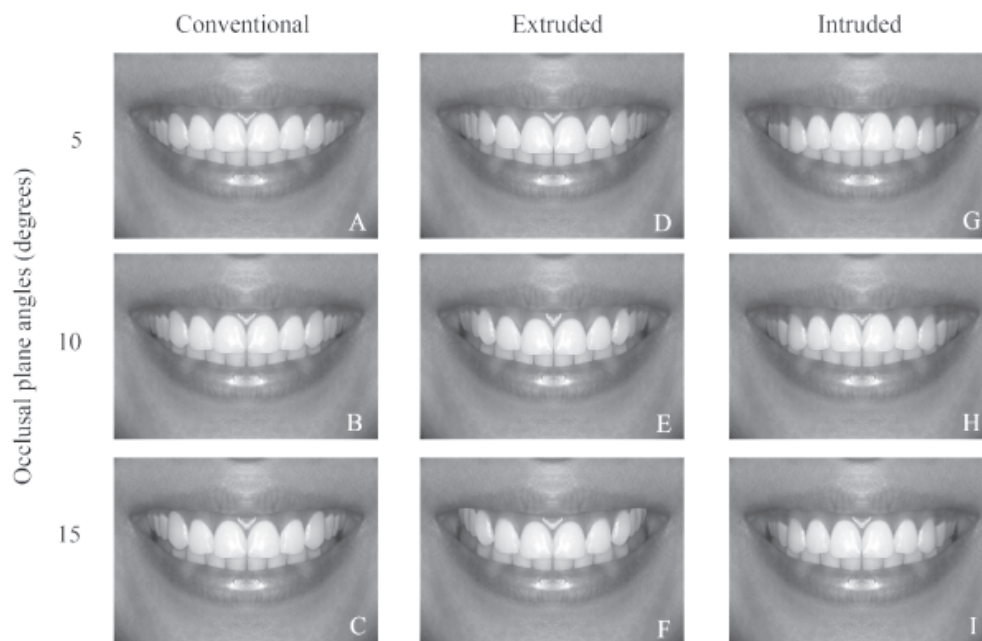


Figure 3. The nine smiles with different bracket positions and OPAs A) Con5, B) Con10, C) Con15, D) Ext5, E) Ext10, F) Ext15, G) Int5, H) Int10, and I) Int15.

Berkshire, United Kingdom) was used to take photographs of each model at OPAs of 5° , 10° and 15° to the true horizontal. An inclinometer application on an iPhone (Apple Inc, Cupertino, CA) and a weighted pendulum were used for angle measurements. Nine photographs of three models at three OPAs were obtained.

Phase 2: Photograph construction

1. Adobe Photoshop CS4 software (Adobe Systems Incorporated, San Jose, CA) was used to morph the nine photographs from Phase 1 onto the posed smile previously taken, using the maxillary lateral incisor gingival line as a reference point. For magnification control, the maxillary lateral incisor width from the photographs and the posed smile were adjusted to be equal.

Table 1: The demographic data and intra-class correlation coefficients of the assessors.

		Orthodontists	Non-orthodontists	Laypeople
Gender	Male	20 (36.4%)	24 (43.6%)	26 (47.3%)
	Female	35 (63.6%)	31 (56.4%)	29 (52.7%)
	Total	55 (100%)	55 (100%)	55 (100%)
Age (years ± S.D.)		37.2 ± 9.6	31.3 ± 5.4	29.0 ± 9.1
Education level attained				
Secondary school		0	0	4 (7.3%)
High school		0	0	8 (14.5%)
Diplomas		0	0	8 (14.5%)
Bachelor's degree		0	26 (47.3%)	22 (40%)
Higher than bachelor's degree		55 (100%)	29 (52.7%)	13 (23.6%)
Experience of orthodontists				
During residency training		8 (14.5%)	-	-
Less than 5 years		25 (45.5%)	-	-
5-10 years		9 (16.4%)	-	-
11-15 years		4 (7.3%)	-	-
16-20 years		3 (5.4%)	-	-
More than 20 years		6 (10.9%)	-	-
Intra-class correlation coefficient		0.81	0.72	0.78
(ICC)		Substantial	Fairly good	Fairly good

2. One side of each photograph was selected. The color of the artificial teeth and the wax of each photograph was replaced with the gingival and tooth colors of the posed smile. Each photograph was duplicated as a mirror image of the selected side to obtain a symmetrical image.

3. The nine photographs representing different bracket positions and OPAs were separately printed on 4 × 6 inch photographic paper and attached to a photograph album, one image per page, in a random order for assessment (Figure 3).

Phase 3: Photographic assessment

1. The sample size was calculated to achieve a power of 80% with an alpha significance level of 0.05, indicating that a sample size of 44 was needed. Three

groups were defined: a sample of Faculty and resident orthodontists, a sample of Faculty and resident dentists (non-orthodontists) and laypeople without a dental professional background randomly selected from Bangkok. Fifty-five assessors were included in each group. The assessors provided their age, sex and education level attained. The orthodontists provided the number of years they have treated orthodontic patients.

2. The assessors viewed each photograph as long as they found necessary. The individuals in each group evaluated the maxillary anterior teeth and rated the attractiveness of each smile photograph in a quiet environment with good lighting using a seven-point Likert scale: 1=Awful, 2=Bad, 3=Fairly bad, 4=Okay, 5=Good, 6=Great or 7=Perfect. The mean smile arc esthetic score of each photograph was calculated.

3. For intra-examiner reliability, 11 assessors (20%) from each group were selected randomly to reassess a second set of the same photographs arranged in a different order.

Statistical analysis

Intra-examiner reliability was evaluated by the Intra-class correlation coefficient. For evaluation of smile attractiveness based on different bracket positions and OPAs, mean scores between images were compared using the Friedman's and Wilcoxon Signed Rank tests at a 0.05 significance level.

Results

The demographic data of the assessors are shown in Table 1.

Reliability

The intra-class correlation coefficient (ICC) for the orthodontists was 0.81, indicating substantial reliability. The ICC for the non-orthodontists and laypeople were 0.72 and 0.78, respectively, indicating fairly good reliability for these groups (Landis and Koch, 1977) (Table 1).

Esthetic Scores

We analyzed the scores based on OPA (Table 2, Fig. 4). We found that, at an OPA of 5°, the Ext5 image was the most attractive compared with the Con5 and Int5 images. When the OPA was increased to 10°, the scores of the Con and the Int group significantly increased with the Con10 image being the most attractive compared with the Ext10 and the Int10 images. When the OPA was increased to 15°, the Con15 and the Ext15 image scores were not significantly different, however, their scores were significantly higher than that of the Int15 image.

At identical bracket positions, the smile arc esthetic score of the Con5 image was assessed significantly lower than that of the Con10 and Con15 images, with the Con10 image being the most attractive. The extruded group obtained the highest score at an OPA of 5° (Ext5 image). Compared by OPA, the scores of the Ext10 and Ext15 images were not significantly different; however, they were significantly lower than that of the Ext5 image. For the intruded group, the smile arc esthetics increased significantly with increasing OPAs (Table 2, Figure 4).

Table 2: Means and standard deviations of smile arc esthetics.

		Bracket positions		
		Conventional	Extruded	Intruded
Occlusal plane angles	5°	4.33 ± 1.3 ^{Aa}	5.68 ± 0.84 ^{Ab}	3.03 ± 1.27 ^{Ac}
	10°	5.69 ± 0.97 ^{Ba}	5.26 ± 0.99 ^{Bb}	3.97 ± 1.27 ^{Bc}
	15°	5.26 ± 0.94 ^{Ca}	5.22 ± 1.11 ^{Ba}	4.73 ± 1.08 ^{Cb}

Different uppercase letters indicate significant differences ($p < 0.05$) of means within the same bracket position. Different lowercase letters indicate significant differences ($p < 0.05$) of means within the same OPA.

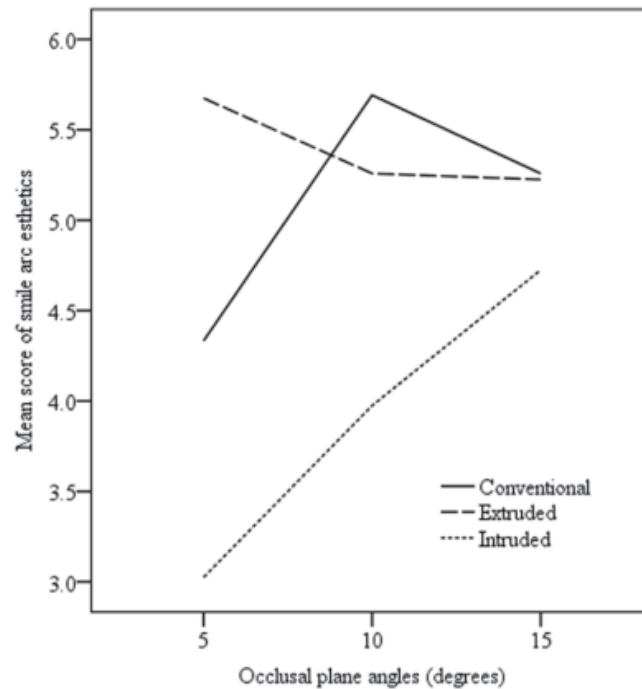


Figure 4: Smile arc esthetic scores.

Considering the three groups of assessors, orthodontists, non-orthodontists and laypeople assessed the smile arc esthetics similarly. The exception was for the extruded group at an occlusal plane angle of 15°, orthodontists scored the smile arc esthetics as less attractive than that at 10°, while non-orthodontists and laypeople assessed it as more attractive (Figure 5).

Discussion

This study evaluated effects of vertical bracket position and occlusal plane angle on smile arc attractiveness. Our findings indicated that vertical bracket position, occlusal plane angle, and the interaction between these two variables affected smile arc esthetic perception.

Our results demonstrated that at an OPA of 5°, the Ext5 image was rated significantly higher compared with the Con5 and the Int5 images. At this angle, the Ext5 image showed an approximately parallel relationship between the maxillary incisal edge curvature and the curvature of the lower lip while the Con5 and the Int5 images demonstrated flat or

reversed smile arcs. At an OPA of 10°, the maxillary anterior tooth display of the three bracket positions increased due to the antero-posterior cant of the occlusal plane. Although the Ext10 image showed a parallel relationship between the lip and incisal edge curvatures, the Con10 image, which showed an almost parallel relationship between the curvatures, was significantly preferred. Finally, at 15°, all bracket positions demonstrated an increased smile arc. The attractiveness of the Con15 and the Ext15 images were not significantly different, however, they were significantly preferred compared with the Int15 image. At this angle, the relationship between the maxillary incisal edge curvature and that of the lower lip of the Con15 image became parallel, while the Ext15 image showed an excessive smile arc. Our results demonstrated that smiles with a close relationship between the maxillary incisal edge curvature and the lower lip curvature had high esthetic scores. However, the degree of the parallelism of these two curvatures that would make the most pleasing smile should be evaluated in further studies.

When evaluating bracket position, although the Con10 image was most pleasing, it did not represent the most consonant smile arc which was presented in the Con15 image. The Ext5 image, which demonstrated an almost parallel relationship between the two curvatures, was the most attractive compared with the Ext10 and Ext15 images. At higher angles, the smile arc of the Ext10 and Ext15 images were assessed as less attractive than at an OPA of 5°, even though they were more curved compared with the Ext5 image. These results agree with those of Wong et al., which found that at higher angles, the curve of the incisal edges tends to display excessive curvature (Wong et al., 2005). Our findings suggest that extruding the maxillary incisors may not enhance the attractiveness of a smile with a normal or high antero-posterior cant of the maxilla. The smile arcs resulted from the intruded group appeared to be flatter than the other groups and their smile arc esthetic scores were significantly lower than the other bracket positions at all OPAs. However, the intruded group displayed a greater smile arc curvatures with increasing OPAs and the attractiveness of the smiles increased almost linearly from an OPA of 5 to 15°. Our results in the intruded group agree with previous studies that demonstrated that increasing the cant of the maxillary occlusal plane to the Frankfort horizontal plane in the natural head position increases maxillary anterior tooth display and improves smile arc consonance (Ackerman and Ackerman, 2002; Grover et al., 2015). Thus, intruding the maxillary anterior teeth may not be as deleterious to smile appearance as previously believed. A previous study showed that, although orthodontic treatment results in incisal edge flattening, it does not lead to a non-consonant smile (Wong et al., 2005). This can be explained by the antero-posterior cant of the occlusal plane that masks the appearance of a flat or reversed smile arc. Therefore,

greater anterior canting results in greater smile arc consonance. Kattadiyil et al. also reported that the esthetic preference for the maxillary occlusal plane is influenced by the viewing angle, with views at 0° and 10° above the occlusal plane being preferred to 10° below the occlusal plane (Kattadiyil et al., 2012). In our study, increasing the viewing angle increased the attractiveness of the smile arcs in only the intruded group.

When the combination of bracket positions and OPAs was considered, among the nine smiles, the Con10 and the Ext5 images were rated as the most attractive. These two smiles had their maxillary incisal edge curvature almost parallel to that of the lower lip. A higher canting of the maxillary occlusal plane may create an excessive smile arc (the Con15, Ext10 and Ext15 images) with decreased attractiveness. These results agree with those of a previous study (Batwa et al., 2012), which found that neither dentists nor patients tolerated smile arcs obtained from extreme OPA deviations. The least attractive smile was the reversed smile arc of the Int5 image, which agrees with previous studies of smile arcs as perceived by various groups of assessors (Tjan et al., 1984; Parekh et al., 2006; Parekh et al., 2007; Ker et al., 2008; Springer et al., 2011; Badran and Mustafa, 2013).

The intra-class correlation coefficients of the non-orthodontists and laypeople in our study were similar to that in a previous study (Batwa et al., 2012). We evaluated two factors: bracket position and OPA, however, in a previous study (Batwa et al., 2012) only the OPA was varied, which may make it easier for assessors to assess one feature of the smile. The intra-class correlation in our study was higher compared with those of two previous studies (Parekh et al., 2007; Badran and Mustafa, 2013). Our findings indicated that the laypeople (ICC = 0.78) were more reliable

compared with the non-orthodontists (ICC = 0.72) corresponding with previous studies (Parekh et al., 2006; Batwa et al., 2012). Interestingly, dentists would be expected to be more objective in their judgment. This finding may be because dentists' concentration on specific features might complicate their smile assessment because there are too many features to consider (Batwa et al., 2012) and the laypeople might assess the smiles with the same score if the photographs had only small differences that were not apparent to them.

A strength of the current study was how the smile arcs at various occlusal planes were created. Unlike most studies that digitally altered the tooth position (Parekh et al., 2006; Springer et al., 2011; Ioi et al., 2013; Machado et al., 2013), our study obtained the smiles by taking photographs of artificial teeth at specific antero-posterior tilts of the occlusal plane. The computer software was used to morph the images of the artificial teeth into the lip frame and replace the color of the artificial teeth and wax with the color of the model's teeth and gingivae. This results in a more realistic perspective of the position of the teeth compared with photographs that are obtained by digitally altering tooth position.

We used OPAs of 5, 10 and 15° to the true horizontal based on the findings of previous studies. Lundström and Lundström reported that the Sella-Nasion (SN) plane, in a natural head position, averages 4° to the true horizontal (Lundstrom and Lundstrom, 1992). Steiner showed that the angle between the occlusal plane and the SN plane is $14 \pm 2.5^\circ$ (Steiner, 1959). This suggests that, on average, the occlusal plane is $10^\circ \pm 2.5^\circ$ to the true horizontal. Previous studies (Solow and Tallgren, 1971; Graber et al., 2012; Kattadiyil et al., 2012) also revealed that the average angle between the Frankfort horizontal plane and the occlusal plane is approximately 10°. A range

of 5–15° was used to ensure that 2 standard deviations were covered on both sides of the mean. Our findings were in the condition that the maxillary anterior teeth were seen from a view that was parallel to the true horizontal.

In present study, the lip frame used for all three OPAs was taken at a natural head position, assuming that the occlusal plane was 10° to the true horizontal. This was to control factors other than the tested determinants that could affect the smile attractiveness evaluation. However, the appearance of the lip frames changes with different viewing angles. Using the same lip frame for all OPAs, the smiles obtained may not represent the exact relationships between the lips and teeth. Moreover, the lip frame was captured from a female Asian smile, which may limit our results to this sex and ethnicity. Furthermore, the assessors were randomly selected from Asian individuals, thus, these findings may not translate to patients of other ethnicities. Lastly, the socioeconomic status of the assessors was not considered, which may be another limitation of our study.

In the pre-adjusted bracket system, the vertical bracket position on the tooth surface can alter the inclination exerted on the tooth. This is a result of the altered surface curvature observed at each vertical position. When the inclination of the anterior teeth altered, the clinical crown length observed from the frontal view was also modified. Although the alterations of the inclination and the clinical crown length resulted from different vertical bracket positions are small, they may affect the perception of smile esthetics. In our study, the clinical crown length of the maxillary anterior teeth was manipulated to be equal among the three vertical bracket positions to control the confounding factor that may affect the perception of smile esthetics and resulted in some weaknesses to

our study.

Another limitation of the present study was that the gingival display among the nine smiles was different and may affect the perception of smile arc esthetics. The assessors may not judging only the vertical position of the teeth, but also the amount of gingival display. However, the modification of the gingival display is unavoidable if the confounding factor, i.e., the clinical crown height needs to be controlled. In our study, the amount of upper gingival display at the anterior and posterior teeth was modified as a result of different occlusal plane angles and our attempt to control the clinical crown height of the dentition. Moreover, previous study on the perception of smile esthetics of the cropped images showing only the altered gingival margin arrangement demonstrated that no statistical difference was found among all smiles, suggesting that gingival margins play only a small role in the overall perception of smile esthetics (Machado et al., 2013). The findings are supported by literature reporting large thresholds for gingival margin discrepancies (Kokich et al., 1999; Kokich et al., 2006; Ker et al., 2008). The clinical implications of our results are that smile arc esthetics does not depend solely on the bracket position; the OPA plays an important role as well. At an average OPA, the smile arc obtained by bracket position according to a guideline based on tooth measurement resulted in the most attractive smile compared with that obtained by bracket positions aimed to extrude and intrude the maxillary incisors. Extruding the maxillary incisors to accentuate the smile arc, the extruded group, was rated as most attractive at a low OPA (5°) and its attractiveness decreased with increasing OPAs. Thus, accentuation of the smile arc is not an absolute indication of maximum esthetics for most patients; however, it is likely to benefit those with a low OPA rather than a normal or high angle. In

contrast, the bracket position intended to intrude the maxillary incisors, which resulted in a flat or reversed smile arc at a normal and low OPAs, can be used in patients with a high OPA because increasing the antero-posterior canting of the occlusal plane masks the appearance of a flat or reversed smile arc.

Conclusions

Vertical bracket position and OPA affected smile arc esthetics. At an average OPA, the smile arc obtained by placing brackets based on tooth measurement resulted in the most attractive smile arc compared with that obtained by bracket positions aimed to extrude or intrude the maxillary incisors. Extruding the maxillary incisors may be advantageous to patients with a low OPA rather than a normal or high OPA, while intruding the maxillary incisors may be used in patients with a high OPA without showing a flat or reversed smile arcs.

Acknowledgements

The study was supported by Faculty Research Grant (DRF 59006), Faculty of Dentistry, Chulalongkorn University. We are grateful to Prof. Martin Tyas, Dr. Kevin Tompkins, and Mr. Ruben Pauwels for their valuable suggestions on the manuscript. The authors do not have any financial interest in the companies whose materials are included in this study.

References

- Ackerman JL, Ackerman MB, Brensinger CM, Landis JR. A morphometric analysis of the posed smile. *Clin Orthod Res.* 1998;1:2-11.
- Ackerman MB, Ackerman JL. Smile analysis and design in the digital era. *J Clin Orthod.* 2002;36:221-36.
- Badran SA, Mustafa M. A comparison between

- laypeople and orthodontists in evaluating the effect of buccal corridor and smile arc on smile esthetics. *J World Fed Orthod.* 2013;2:e123–e6.
- Batwa W, Hunt NP, Petrie A, Gill D. Effect of occlusal plane on smile attractiveness. *Angle Orthod.* 2012;82:218–23.
- Downs WB. Variations In facial relationship: their significance in treatment and prognosis. *Angle Orthod.* 1949;19:145–55.
- Graber LW, Vanarsdall Jr RL, Vig KWL. Standard edgewise: Tweed–Merfield philosophy, diagnosis, treatment planning, and force system In: John D, Kristin H, Joslyn D, editors. *Orthodontics current principles and techniques.* 5th ed. USA: Elsevier Health Sciences; 2012. p. 529–59.
- Grover N, Kapoor D, Verma S, Bharadwaj P. Smile analysis in different facial patterns and its correlation with underlying hard tissues. *Prog Orthod.* 2015;16:1–13.
- Hilgers JJ, Farzin–Nia F. The asymmetrical “T” archwire. *J Clin Orthod.* 1992;26:81–6.
- Ioi H, Kang S, Shimomura T, Kim SS, Park SB, Son WS, et al. Effects of vertical positions of anterior teeth on smile esthetics in Japanese and Korean orthodontists and orthodontic patients. *J Esthet Restor Dent.* 2013;25:274–82.
- Kattadiyil MT, Goodacre CJ, Naylor WP, Maveli TC. Esthetic smile preferences and the orientation of the maxillary occlusal plane. *J Prosthet Dent.* 2012;108:354–61.
- Ker AJ, Chan R, Fields HW, Beck M, Rosenstiel S. Esthetics and smile characteristics from the layperson’s perspective: a computer–based survey study. *J Am Dent Assoc.* 2008;139:1318–27.
- Kokich VO, Kokich VG, Kiyak HA. Perceptions of dental professionals and laypersons to altered dental esthetics: asymmetric and symmetric situations. *Am J Orthod Dentofacial Orthop.* 2006;130:141–51.
- Kokich VO, Jr., Kiyak HA, Shapiro PA. Comparing the perception of dentists and lay people to altered dental esthetics. *J Esthet Dent.* 1999;11:311–24.
- Landis JR, Koch GG. The measurement of observer agreement for categorical data. *Biometrics.* 1977;33:159–74.
- Lundstrom F, Lundstrom A. Natural head position as a basis for cephalometric analysis. *Am J Orthod Dentofacial Orthop.* 1992;101:244–7.
- Machado AW, McComb RW, Moon W, Gandini LG, Jr. Influence of the vertical position of maxillary central incisors on the perception of smile esthetics among orthodontists and laypersons. *J Esthet Restor Dent.* 2013;25:392–401.
- Parekh S, Fields HW, Beck FM, Rosenstiel SF. The acceptability of variations in smile arc and buccal corridor space. *Orthod Craniofacial Res.* 2007;10:15–21.
- Parekh SM, Fields HW, Beck M, Rosenstiel S. Attractiveness of variations in the smile arc and buccal corridor space as judged by orthodontists and laymen. *Angle Orthod.* 2006;76:557–63.
- Pitts TR. Begin with the end in mind: bracket placement and early elastics protocols for smile arc protection. *Clin Impres.* 2009;17:4–13.
- Sabri R. The eight components of a balanced smile. *J Clin Orthod.* 2005;39:155–67.
- Sarver DM. The importance of incisor positioning in the esthetic smile: the smile arc. *Am J Orthod Dentofacial Orthop.* 2001;120:98–111.
- Solow B, Tallgren A. Natural head position in standing subjects. *Acta Odontol Scand.* 1971;29:591–607.
- Springer NC, Chang C, Fields HW, Beck FM, Firestone

- AR, Rosenstiel S, et al. Smile esthetics from the layperson's perspective. *Am J Orthod Dentofacial Orthop.* 2011; doi: 10.1016/j.ajodo.2010.06.019.
- Steiner CC. Cephalometrics in clinical practice. *Angle Orthod.* 1959;29:8-29.
- Tjan AH, Miller GD, The JG. Some esthetic factors in a smile. *J Prosthet Dent.* 1984;51:24-8.
- Unitek. MBT Versatile+ Appliance Bracket Placement Guide 2015. <http://multimedia.3m.com/mws/media/96705O/mbt-versatile-bracket-placement-guide-ifu.pdf>. Accessed 15 Sep 2015.
- Wong NK, Kassim AA, Foong KW. Analysis of esthetic smiles by using computer vision techniques. *Am J Orthod Dentofacial Orthop.* 2005; 128:404-11.