



Original Article

บทความวิชาการ

The effect of marginal recession around anterior maxillary implants on the esthetic satisfaction assessed by the patient and the clinician

Supreda Suphanantachat, D.D.S.¹

Ketsuda Thovanich, D.D.S., M.Sc. (Prosthodontics)²

Kanokwan Nisapakultorn, D.D.S., Ph.D., Diplomate, American Board of Periodontology³

¹Graduate student, Department of Periodontology, Faculty of Dentistry, Chulalongkorn University

²Implantology Unit, Faculty of Dentistry, Chulalongkorn University

³Department of Periodontology, Faculty of Dentistry, Chulalongkorn University

Abstracts

Objective The purpose of this study was to assess and compare patients' and clinicians' judgments of the esthetic outcome of single-tooth anterior maxillary implants. In addition, the effect of facial marginal recession on the rating of esthetic outcomes was evaluated.

Materials and methods Thirty patients restored with single-tooth anterior maxillary dental implants from the Faculty of Dentistry, Chulalongkorn University were recruited for the study. The patients were asked to rate their satisfaction on four esthetic and four lifestyle-related variables using visual analog scale (VAS). Six clinicians, including 2 periodontists, 2 orthodontists and 2 prosthodontists, were given the clinical photograph of these implants and were also asked to rate their satisfaction on esthetic-related variables. The VAS score of the patient and clinician on the same variables was compared and the correlation between these scores was determined. Binary logistic regression was used to analyze the effect of each variable on overall esthetic satisfaction. Furthermore, the effect of facial marginal recession on the rating of each esthetic-related variable was assessed.

Results For esthetic-related variables, the patients showed high overall esthetic satisfaction (85.9%), and high satisfaction on crown shape and color. However, their satisfaction on the harmonization of gingival margin was relatively low (66.6%). For lifestyle-related variables, high satisfaction was shown for all except for the comfort when chewing or biting (70.1%). The VAS score of the clinicians was statistically significantly lower than that of patients for all variables ($p < 0.05$). No correlation was found between the VAS score given by patients and clinicians for all esthetic-related variables. The presence of facial marginal recession had no significant effect on the VAS scores assessed by patients towards all esthetic-related variables, including the harmonization of gingival margin itself. In contrast, facial marginal recession significantly affected the VAS score rated by clinicians, especially by periodontists.

Conclusion Patients were highly satisfied with the outcome of their single-tooth anterior maxillary implants. Clinicians, however, showed lower degree of satisfaction than patients. There was no correlation between patients' and clinicians' judgment towards esthetic outcomes. Facial marginal recession, which is considered critical for esthetic satisfaction by clinicians, did not appear to be significant for esthetic satisfaction from the patients' standpoint.

(CU Dent J. 2010;33:1-14)

Key words: dental implant; esthetic; gingival recession; patient satisfaction; visual analog scale

Introduction

Dental implants have become a standard of care for tooth replacement. Long term studies demonstrated high survival rate and success rate of dental implants. A systematic review that included prospective longitudinal studies with follow-up periods of at least 5 years showed that the survival rate for various types of implant restorations ranged from 91-97% whereas the success rate, as determined by the loss of crestal bone less than 2.5 mm, ranged from 86-96%.¹ While tooth replacement with dental implants is predictable in terms of function, achieving successful implant esthetics, especially in the anterior maxilla, is challenging. Successful implant esthetics required high quality implant restorations as well as gingival architecture that harmonized with the adjacent natural teeth.

Peri-implant soft tissue recession is considered a major implant esthetic complication. A mean marginal recession of 0.6-1.5 mm around dental implants has

been reported.²⁻⁵ Small and Tarnow⁵ found that recession occurred in most of the implant restorations during the first 3 months following abutment connection surgery. The majority of recession (80%) occurred on the buccal aspects with the mean recession of 0.9 mm and more pronounced in maxillary teeth. Oates et al.⁴ studied the mucosal recession in maxillary and mandibular anterior implants over 2 years. They found the mean recession of 0.6 mm. Sixty percent of the implants showed recession ≥ 1 mm. Jemt et al.⁶ retrospectively examined the study casts of 23 patients who received single implant restorations in the anterior maxilla for an average of 15 years. They found that the implant clinical crowns were an average 0.6 ± 1.04 mm longer than the contralateral teeth. Seventeen percent of the implant crowns showed recession ≥ 1 mm. It appeared that marginal recession was relatively common among anterior implants. Whether this factor influences the patient's satisfaction with dental implant treatment is unclear.

The patient's esthetic satisfaction is an important criterion for implant success. However, few studies have addressed this aspect when evaluating the implant success's outcome. Implant esthetic can be rated in a subjective and an objective manner. In the subjective method, questionnaires are commonly used.⁷⁻¹⁴ The judgment of favorable implant esthetics appeared to be different between patients and clinicians. Patients were more likely to give higher satisfaction scores than clinicians.^{7,11,15,16} Chang et al.⁷ compared patients' and prosthodontists' judgment of esthetic outcome of maxillary anterior single-tooth implant restorations. They found that the clinician's satisfaction was influenced by multiple factors, including surrounding soft tissue appearance, crown form, contact point position, and crown color. In contrast, no single factor was found to significantly influence the patient's satisfaction. Besides the esthetic standpoint, the dental implant therapy has been shown to improve the patient's quality of life.¹⁷ Therefore, lifestyle-related factors, such as comfort when chewing or biting, speaking, confidence when smiling, and cost, may also be of concern for the patient to justify the outcome of therapy.

Recently, several objective criteria for assessing the esthetic outcome of dental implant have been developed. Meijer et al.¹⁸ published the esthetic implant crown index consisting of criteria related to implant restorations and the surrounding soft tissues. Furhauser et al.¹⁹ developed an index called the pink esthetic score (PES) which focuses mainly on the soft tissue aspect around anterior implants. Belser et al.²⁰ proposed the white esthetic score (WES) which specifically focuses on the implant restoration. These indices were available for the professionals to objectively assess the esthetic outcome of dental implants. However, the validity of these indices has not been widely investigated.¹⁵

The purpose of this study was to assess and compare patients' and clinicians' judgments of the esthetic outcome of single-tooth anterior maxillary

implants. In addition, the effect of facial marginal recession on the rating of esthetic outcomes was evaluated.

Materials and methods

Study samples

The list of patients who received dental implant treatment at the Faculty of Dentistry, Chulalongkorn University between the year 1999-2008 was reviewed. The patients who met the following criteria were invited to participate in the study: 1) had a single-tooth implant in the anterior maxilla 2) had a natural contralateral tooth 3) the implant was restored and in function for at least 6 months. Thirty patients agreed to participate in the study and 30 single-tooth implants were included for analysis. Informed consent was obtained from all subjects. The study protocol was approved by the ethic committee of the Faculty of Dentistry, Chulalongkorn University (number 89/2008).

Determining the presence of facial marginal recession

The presence of facial marginal recession was determined from the study model. The clinical crown height of an implant and the contralateral natural tooth was measured from incisal edge to gingival margin at mid-facial using a digimatic caliper (Mitutoyo, Japan), measured to the closet 0.1 mm. Facial marginal recession was calculated by subtracting the clinical crown height of an implant from the contralateral tooth. The marginal recession was considered "presence" if the clinical crown height of an implant was 1 mm or longer (≥ 1 mm) than that of the contralateral tooth.

Assessment of patient satisfaction

A Thai-language questionnaire composed of 8 questions was used to assess the patient satisfaction using visual analog scale (VAS). The questions were

categorized into 2 groups, esthetic-related variables (4 questions) and lifestyle-related variables (4 questions). For esthetic-related variables, the patients were asked about their satisfaction with harmonization of gingival margin, crown shape, crown color, and overall esthetic satisfaction. For lifestyle-related variables, the patients were asked about their satisfaction with implants in terms of confidence when smiling, comfort when chewing or biting, speaking well, and worth for the expense. The patients were asked to mark their assessment on a 100-mm line having end phrases “not satisfied at all” on the left and “very satisfied” on the right. The distance from the left end of the VAS to the mark made by the patient was measured to the nearest millimeter and reported as a percentage. The patients completed the questionnaire at the time of participation.

Assessment of clinician satisfaction

Six clinicians, comprising of two periodontists, two prosthodontists and two orthodontists who were not involved in the treatment of the patients, were recruited to assess their satisfaction with dental implants of the study samples. The frontal view intraoral photographs were taken from 30 patients using a Nikon D80 digital camera with macro lens and ring flash with a magnification of 1:1.2. Digital images were shown on the LCD projector screen (Sony VPL-CX86 wireless network projector, New Jersey, USA). The clinicians were asked to rate their satisfaction on esthetic-related variables using four-VAS questions which shared the same content and format as those used for the patient assessments.

Statistical analysis

Commercially available statistical software, SPSS version 13.0 and SigmaStat® for Windows version 2.03 (SPSS Inc, Chicago, Illinois, USA), were utilized for data analysis. The dependent variable in this study was the VAS score. Descriptive analyses, i.e., mean and standard deviation, of the VAS score across study

samples were performed. The comparison of patients' and clinicians' VAS scores was analyzed by paired-sample T test. The correlation analysis between the VAS score of patients and those of clinicians was tested by Pearson correlation analysis. The differences of the VAS score among the group of specialties were analyzed by multiple comparisons, Tukey test. The association between the presence of marginal recession and the VAS score assessed by patients and clinicians was analyzed by independent sample T-test or Mann Whitney U test depended on the characteristic of the sample's distribution. Finally, the binary logistic regression was performed to evaluate the influence of the independent variables on overall esthetic satisfaction scores assessed by the clinicians. The VAS score on “overall esthetic satisfaction” was categorized into 2 groups. The VAS score < 50% was referred to a “not satisfied” group and the VAS score \geq 50% was referred to a “satisfied” group.²¹ Crude and adjusted odd ratios (ORs) and 95% confidence intervals (95% CIs) were calculated. The level of statistical significance was at $p < 0.05$ for all statistical tests.

Results

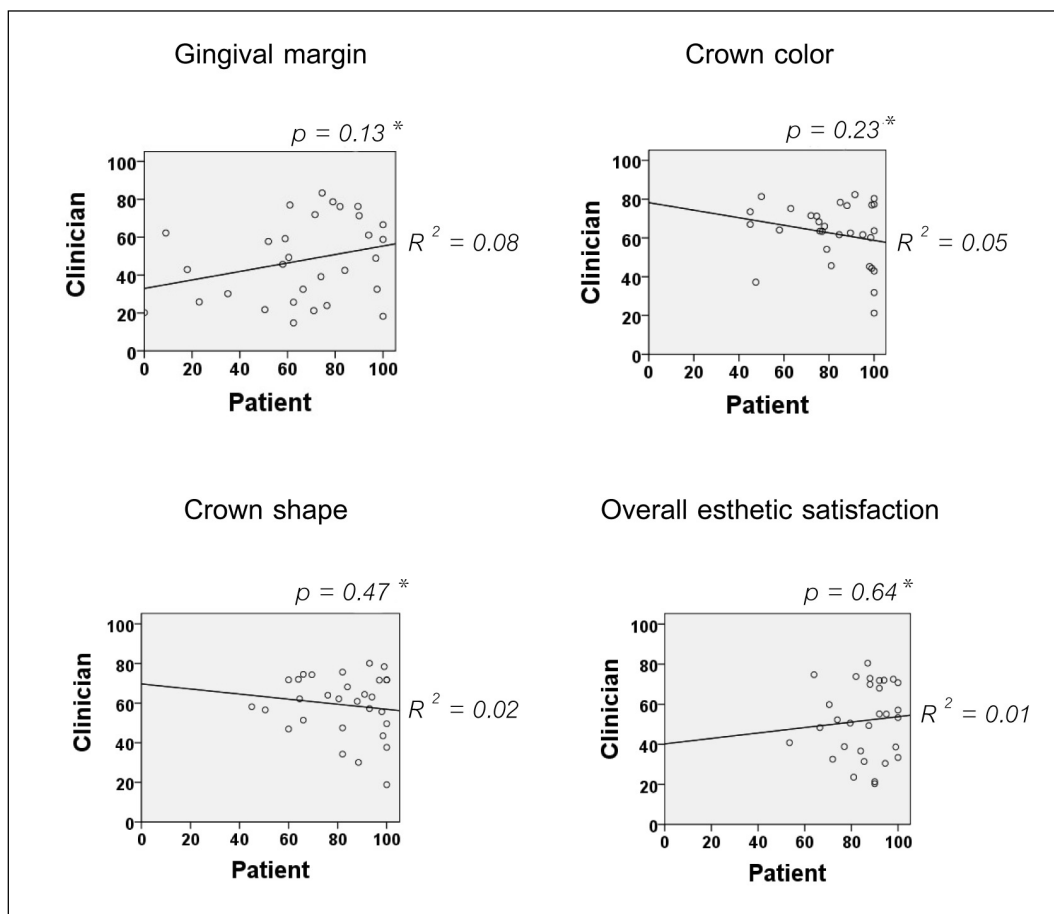
This study included 30 patients with 30 single-tooth implants on the anterior maxilla. The demographic characteristics of the study group were shown in Table 1. The mean age was 42 years old, ranging from 22-71 years. Forty-seven percent of the subjects were men and 53.3% were women. The majority of dental implants (76.7%) were the central incisors. The average facial marginal recession was 0.6 ± 0.9 mm. One-third of the samples had the facial marginal recession ≥ 1 mm.

The patients' and clinicians' satisfaction on the dental implants was shown in Table 2. For esthetic-related variables, the patients showed high overall esthetic satisfaction (85.9%), and high satisfaction on crown shape and color. However, their satisfaction on the harmonization of gingival margin was relatively

low (66.6%). For lifestyle-related variables, high satisfaction scores were shown for all except for the comfort when chewing or biting (70.1%). Overall, the patient thought that the dental implant treatment was worth the expense with the highest satisfaction score of 90.9%. When the VAS score between the clinicians and the patients was compared, we found that the VAS score of the clinicians was statistically significantly lower than that of patients for all variables. We also found no significant difference in the VAS score among gender for all variables (data not shown). We further asked whether the VAS score given by clinicians and patients were correlated. As shown in Figure 1, there was no correlation between the patient and clinician satisfaction for all esthetic-related variables.

To determine whether each dental specialty had different esthetic satisfaction, we compared the VAS score of esthetic-related variables among orthodontists, periodontists, and prosthodontists. The data were shown in Figure 2. The mean overall esthetic satisfaction score was 43.6% for orthodontists, 55.5% for periodontists, and 56.6% for prosthodontists, respectively. A multiple comparisons by Tukey test revealed a significant lower VAS score on “overall esthetic satisfaction” rated by orthodontists than prosthodontists and periodontists ($p < 0.001$). The VAS score on “harmonization of gingival margin” was also rated lower among orthodontists than prosthodontists ($p < 0.001$). The clinician’s satisfaction with crown shape and color was not significantly different among specialties.

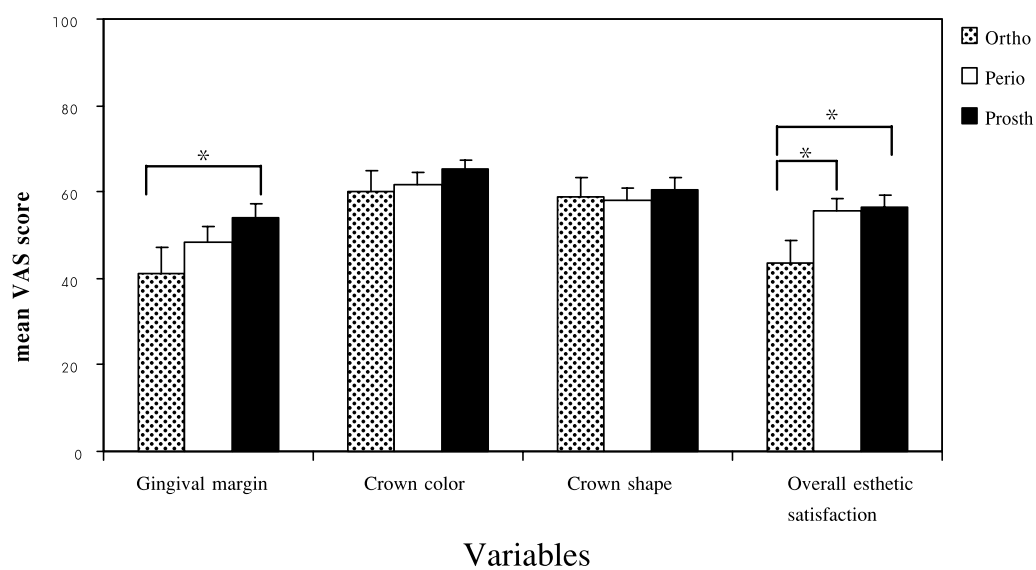
Figure 1 Correlation between patients’ and clinicians’ VAS score for each esthetic-related variable.



*Analyzed by Pearson correlation.

Table 1 Descriptive characteristics of the study samples (n = 30).

Variable	Frequency (%)
Gender	
Male	14 (46.7)
Female	16 (53.3)
Facial marginal recession	
Presence (≥ 1 mm)	10 (33.3)
Absence (< 1 mm)	20 (66.7)
Implant location	
Central incisors	23 (76.7)
Lateral incisors	5 (16.7)
Canines	2 (6.6)

Figure 2 Comparison of the VAS score of esthetic-related variables among different dental specialties.

Analyzed by multiple comparisons; Tukey test.

*Statistically significant between groups ($p < 0.001$).

Table 2 The VAS score for esthetic-related variables (1-4) and lifestyle-related variables (5-8) assessed by patients and clinicians.

Variable	Patients	Clinicians	p-value*
	mean (S.D.)	mean (S.D.)	
1. Harmonization of gingival margin	66.6 (27.4)	47.9 (21.6)	0.002
2. Crown color	81.7 (18.2)	62.3 (15.7)	< 0.001
3. Crown shape	82.4 (16.5)	59.1 (15.3)	< 0.001
4. Satisfaction with esthetic	85.9 (11.9)	51.9 (18.2)	< 0.001
5. Confidence when smiling	81.0 (16.9)	-	-
6. Comfort when chewing or biting	70.1 (24.7)	-	-
7. Speaking well	86.8 (16.3)	-	-
8. Worth for the expense	90.9 (11.8)	-	-

S.D. = standard deviation

*Analyzed by paired-sample T test.

We further analyzed which variables had significant influence on the clinician’s overall esthetic satisfaction. The binary logistic regression analysis was applied to evaluate the effect of harmonization of gingival margin, crown color, and crown shape on overall esthetic satisfaction. As shown in Table 3, all three

variables (gingival margin, crown color and shape) significantly affected overall esthetic satisfaction rated by clinicians. However, the harmonization of gingival margin was the only variable that remained significant after adjusted for the confounders ($p = 0.03$, 95%CI = 1.01-1.29), as shown by adjusted odd ratios.

Table 3 Crude and adjusted odd ratios (ORs) and 95% confidence interval of variables that were related to clinicians’ overall esthetic satisfaction.

Variable	Crude OR (95% CI)	p-value	Adjusted OR (95% CI)	p-value
Harmonization of gingival margin	1.15 (1.05-1.25)	0.003	1.14 (1.01-1.29)	0.031
Crown color	1.07 (1.00-1.13)	0.037	1.10 (0.95-1.28)	0.191
Crown shape	1.15 (1.04-1.28)	0.006	1.21 (0.93-1.56)	0.159

Finally, we examined whether the presence of facial marginal recession (≥ 1 mm) affected the VAS score assessed by patients and clinicians. The data were shown in Table 4. We found that facial marginal recession had no significant effect to any esthetic-related variables assessed by patients. In contrast, the presence of recession significantly affected all variables assessed by periodontists. For orthodontists, facial marginal recession influenced their VAS scores on harmonization of gingival margin, overall esthetic satisfaction and crown shape, but not the crown color. For prosthodontists, facial marginal recession influenced their VAS scores on harmonization of gingival margin and overall esthetic satisfaction, but not the crown shape and crown color.

Discussion

The dental implant therapy is expected to improve the patients' quality of life, in terms of both function and esthetic. Patient-based treatment outcomes, therefore, should be an important justified criteria of

success, besides the objective criteria judged by the clinician.²² However, this aspect of treatment outcome has not been adequately recognized in the literatures. For anterior maxillary implants, esthetic becomes an important success criteria. However, it is unclear whether the patients and clinicians have the same perspective for esthetics. Therefore, the purpose of this study was to assess and compare patients' and clinicians' judgments of the esthetic outcome of single-tooth anterior maxillary implants. In addition, the effect of facial marginal recession on the rating of esthetic outcomes was evaluated.

The patients included in the present study showed high overall esthetic satisfaction (85.9%). The result was in agreement with previous studies which reported above 85% VAS score on the satisfaction with esthetic and function of single-tooth implant restorations.^{7,8,13,14} However, the satisfaction score for the harmonization of gingival margin was relatively low (66.6%). This may be due to the fact that one-third of the study subjects had the facial marginal recession ≥ 1 mm.

Table 4 Association between the presence of marginal recession and the average VAS scores assessed by patients and clinicians.

Variable	Patients (<i>p</i> -value)	Periodontists (<i>p</i> -value)	Orthodontists (<i>p</i> -value)	Prosthodontists (<i>p</i> -value)
Harmonization of gingival margin	0.847	0.001	< 0.001	< 0.001
Crown color	0.128	0.007	0.553*	0.344*
Crown shape	0.242	< 0.001	0.017*	0.235
Overall esthetic satisfaction	0.187	< 0.001	0.001	0.007

Analyzed by Mann-Whitney U test (*) or independent samples T-test.

Nonetheless, the presence of marginal recession alone did not appear to affect their overall esthetic satisfaction. When lifestyle-related variables were evaluated, the patients gave the highest satisfaction score to the “worth for the expense” variable (90.9%). This implied that the patients perceived dental implant treatment as worthwhile although it costs higher than other methods of tooth replacement. The patients gave a relatively low VAS score for the “comfort when biting or chewing” variable (70.1%). Moberg et al.¹⁰ also observed the similar finding. Approximately one-third of their study subjects that received single-tooth maxillary implants reported that they avoided chewing and biting with their implants. The patients should, therefore, be informed that implant restorations are not more prone to damage caused by normal diet than natural teeth or other type of restorations.

The patients’ and clinicians’ judgment of the esthetic outcome of single-tooth implants was compared. For all esthetic-related variables, we showed that clinicians gave significantly lower satisfaction score than patients. The previous studies also reported a similar finding which indicated that the clinicians were more critical than the patients in terms of esthetic satisfaction.^{7,11} To determine whether the degree of satisfaction of the patients and the clinicians was correlated, we used Pearson correlation analysis. The data showed no significant correlation between patients’ and clinicians’ VAS scores for all esthetic-related variables. This implied that patients and clinicians may have different perspectives on dental esthetics. Future researches are needed to clarify this discrepancy since it is critical for patient and clinician communications, particularly in esthetic cases.

The degree of overall esthetic satisfaction was different among dental specialties. Orthodontists had lowest level of esthetic satisfaction whereas the level of esthetic satisfaction assessed by periodontists and prosthodontists was not different. Orthodontists were also more critical to the harmonization of gingival margin than prosthodontists. It is possible that periodontists and prosthodontists are involved in implant therapy and are therefore more understandable to the implant outcome. Furhauser et al.¹⁹ demonstrated the significantly lower satisfaction score on the esthetic of soft tissue around single-tooth implant crowns (pink esthetic score; PES) rated by orthodontists as compared to oral surgeons or prosthodontists. These findings emphasized the effect of specialization on the judgment of an esthetic outcome for dental implant therapy.

Several factors had been shown to influence the clinician’s implant satisfaction. Chang et al.⁷ found that soft tissue appearance, crown form, contact point position, and crown color had significant effect on the clinicians’ overall satisfaction with implant appearance. We also found that harmonization of gingival margin, crown color, and crown shape were all affected the clinician overall esthetic satisfaction. However, after adjustment for confounders, harmonization of gingival margin appeared to be the most critical factor that determined clinician’s overall esthetic satisfaction.

Since harmonization of gingival margin was considered critical for clinician’s overall esthetic satisfaction, we further assessed whether having marginal recession affected the patients’ and clinicians’ judgment on esthetic-related variables. Interestingly, marginal recession had no effect on the patients’ satisfaction towards all esthetic-related variables,

including the harmonization of gingival margin itself. Chang et al.⁷ also did not find any single factor that have a significant impact on the patients' satisfaction. The presence of marginal recession affected the satisfaction score of each specialty differently. For prosthodontists, the presence of marginal recession significantly affected their satisfaction scores on harmonization of gingival margin and overall esthetic satisfaction. However, the scores on crown color and crown shape were not affected. On the contrary, the presence of marginal recession, not only affected the satisfaction score rated by periodontists for harmonization of gingival margin and overall esthetic satisfaction, but also for the crown color and crown shape. Marginal recession also affected orthodontists on their judgments of harmonization of gingival margin, overall esthetic satisfaction, and crown shape. These differences may reflect what each specialty was trained to focus well. For instance, the periodontist's judgment on crown shape and crown color was highly influenced by the presence of facial marginal recession since they were trained to focus on soft tissue. Poor soft tissue contour, therefore, lowered their satisfaction towards the adjacent crowns. On the other hand, prosthodontists were trained to focus on the restorations. Therefore, the facial marginal recession did not appear to affect their judgments of crown shape and color.

Conclusion

The result of this study demonstrated that patients were highly satisfied with the outcome of their single-tooth anterior maxillary implants. Clinicians, however, showed lower degree of satisfaction than patients. There was no correlation between patients' and clinicians' judgment towards esthetic outcomes,

including harmonization of gingival margin, crown shape, crown color, and overall esthetic satisfaction. Facial marginal recession, which is considered critical for esthetic satisfaction by clinicians, did not appear to be significant for esthetic satisfaction from the patients' standpoint. The discrepancy between patients' and clinicians' judgment on esthetic warranted further studies.

Acknowledgements

The authors would like to thank Miss Paipan Phitayanon for her assistance with statistical analysis. This study was supported by the 90th Anniversary of Chulalongkorn University Fund (Ratchadapiseksomphot Endowment Fund).

References

1. Berglundh T, Persson L, Klinge B. A systematic review of the incidence of biological and technical complications in implant dentistry reported in prospective longitudinal studies of at least 5 years. *J Clin Periodontol.* 2002;29 Suppl 3:197-212; discussion 32-3.
2. Cardaropoli G, Lekholm U, Wennstrom JL. Tissue alterations at implant-supported single-tooth replacements: a 1-year prospective clinical study. *Clin Oral Implants Res.* 2006;17:165-71.
3. Kan JY, Rungcharassaeng K, Umezaki K, Kois JC. Dimensions of peri-implant mucosa: an evaluation of maxillary anterior single implants in humans. *J Periodontol.* 2003;74:557-62.
4. Oates TW, West J, Jones J, Kaiser D, Cochran DL. Long-term changes in soft tissue height on

- the facial surface of dental implants. *Implant Dent.* 2002;11:272-9.
5. Small PN, Tarnow DP. Gingival recession around implants: a 1-year longitudinal prospective study. *Int J Oral Maxillofac Implants.* 2000;15:527-32.
 6. Jemt T, Ahlberg G, Henriksson K, Bondevik O. Changes of anterior clinical crown height in patients provided with single-implant restorations after more than 15 years of follow-up. *Int J Prosthodont.* 2006;19:455-61.
 7. Chang M, Odman PA, Wennstrom JL, Andersson B. Esthetic outcome of implant-supported single-tooth replacements assessed by the patient and by prosthodontists. *Int J Prosthodont.* 1999;12:335-41.
 8. Chang M, Wennstrom JL, Odman P, Andersson B. Implant supported single-tooth replacements compared to contralateral natural teeth. Crown and soft tissue dimensions. *Clin Oral Implants Res.* 1999;10:185-94.
 9. Levi A, Psoter WJ, Agar JR, Reisine ST, Taylor TD. Patient self-reported satisfaction with maxillary anterior dental implant treatment. *Int J Oral Maxillofac Implants.* 2003;18:113-20.
 10. Moberg LE, Kondell PA, Kullman L, Heimdahl A, Gynther GW. Evaluation of single-tooth restorations on ITI dental implants. A prospective study of 29 patients. *Clin Oral Implants Res.* 1999;10:45-53.
 11. Palmer RM, Farkondeh N, Palmer PJ, Wilson RF. Astra Tech single-tooth implants: an audit of patient satisfaction and soft tissue form. *J Clin Periodontol.* 2007;34:633-8.
 12. Vermylen K, Collaert B, Linden U, Bjorn AL, De Bruyn H. Patient satisfaction and quality of single-tooth restorations. *Clin Oral Implants Res.* 2003;14:119-24.
 13. Wannfors K, Smedberg JI. A prospective clinical evaluation of different single-tooth restoration designs on osseointegrated implants. A 3-year follow-up of Branemark implants. *Clin Oral Implants Res.* 1999;10:453-8.
 14. De Rouck T, Collys K, Cosyn J. Immediate single-tooth implants in the anterior maxilla: a 1-year case cohort study on hard and soft tissue response. *J Clin Periodontol.* 2008;35: 649-57.
 15. den Hartog L, Slater JJ, Vissink A, Meijer HJ, Raghoobar GM. Treatment outcome of immediate, early and conventional single-tooth implants in the aesthetic zone: a systematic review to survival, bone level, soft-tissue, aesthetics and patient satisfaction. *J Clin Periodontol.* 2008;35:1073-86.
 16. Gibbard LL, Zarb G. A 5-year prospective study of implant-supported single-tooth replacements. *J Can Dent Assoc.* 2002;68:110-6.
 17. Cibirka RM, Razzoog M, Lang BR. Critical evaluation of patient responses to dental implant therapy. *J Prosthet Dent.* 1997;78:574-81.
 18. Meijer HJ, Stellingsma K, Meijndert L, Raghoobar GM. A new index for rating aesthetics of implant-supported single crowns and adjacent soft tissues--the Implant Crown Aesthetic Index. *Clin Oral Implants Res.* 2005;16:645-9.
 19. Furhauser R, Florescu D, Benesch T, Haas R, Mailath G, Watzek G. Evaluation of soft tissue around single-tooth implant crowns: the pink esthetic score. *Clin Oral Implants Res.* 2005;16:639-44.
 20. Belser UC, Grutter L, Vailati F, Bornstein MM, Weber HP, Buser D. Outcome evaluation of early placed maxillary anterior single-tooth implants using objective esthetic criteria: a cross-sectional, retrospective study in 45 patients with a 2-to 4-year

- follow-up using pink and white esthetic scores. *J Periodontol.* 2009;80:140-51.
21. Lamb DJ, Ellis B. Comparisons of patient self-assessment of complete mandibular denture security. *Int J Prosthodont.* 1996;9:309-14.
22. Zarb GA, Albrektsson T. Consensus report: towards optimized treatment outcomes for dental implants. *J Prosthet Dent.* 1998;80:641.

ผลของการมีขอบเหงือกกร่นบริเวณรากเทียม พื่นหน้าบนต่อความพึงพอใจด้านความ สวยงามเมื่อประเมินโดยผู้ป่วยและทันตแพทย์

สุปรีดา สุภนนตชาติ ท.บ.¹

เกศสุดา ไทวนิช ท.บ., วท.ม. (ทันตกรรมประดิษฐ์)²

กนกวรรณ นิสกุลธรร ท.บ., Ph.D., Diplomate, American Board of Periodontology³

¹นิสิตบัณฑิตศึกษา ภาควิชาปริทันตวิทยา คณะทันตแพทยศาสตร์ จุฬาลงกรณ์มหาวิทยาลัย

²หน่วยทันตกรรมรากเทียม คณะทันตแพทยศาสตร์ จุฬาลงกรณ์มหาวิทยาลัย

³ภาควิชาปริทันตวิทยา คณะทันตแพทยศาสตร์ จุฬาลงกรณ์มหาวิทยาลัย

บทคัดย่อ

วัตถุประสงค์ เพื่อประเมินและเปรียบเทียบความพึงพอใจของผู้ป่วยและทันตแพทย์ ในแง่ของความสวยงามภายหลังการทำรากเทียมบริเวณพื่นหน้าบน และศึกษาถึงผลของการมีขอบเหงือกกร่นทางด้านใบหน้าต่อระดับความพึงพอใจในความสวยงามของรากเทียม

วัสดุและวิธีการ ผู้ป่วยจำนวน 30 ราย ซึ่งได้รับการฝังรากเทียมบริเวณพื่นหน้าบน จากคณะทันตแพทยศาสตร์ จุฬาลงกรณ์มหาวิทยาลัย ทำการตอบแบบสอบถามเพื่อประเมินความพึงพอใจต่อผลการรักษาด้วยรากเทียม ซึ่งประกอบไปด้วยหัวข้อคำถามซึ่งมีตัวแปรที่เกี่ยวข้องกับความสวยงาม และการดำเนินชีวิต หัวข้อละ 4 ตัวแปร ด้วยวิธีวิซวลอะแนลลิซีสเกล ทันตแพทย์จำนวน 6 คน ประกอบด้วยทันตแพทย์สาขาปริทันตวิทยา ทันตกรรมจัดฟัน และทันตกรรมประดิษฐ์ สาขาวิชาละ 2 คน ทำการประเมินความสวยงามของรากเทียมบริเวณพื่นหน้า จากภาพถ่ายทางคลินิกของผู้ป่วยแต่ละราย นำค่าคะแนนวิซวลอะแนลลิซีสเกลของผู้ป่วยกับทันตแพทย์มาทำการเปรียบเทียบและศึกษาความสัมพันธ์ของตัวแปรที่เกี่ยวข้องกับความสวยงาม ศึกษาอิทธิพลของแต่ละตัวแปรที่มีต่อการให้คะแนนความพึงพอใจของทันตแพทย์ในเรื่องของความสวยงาม ด้วยการใช้วิเคราะห์การถดถอยโลจิสติกแบบตัวแปรทวิ รวมทั้งศึกษาถึงผลของการมีขอบเหงือกกร่นบริเวณรากเทียมต่อระดับความพึงพอใจของผู้ป่วยและทันตแพทย์

ผลการศึกษา ผู้ป่วยมีความพึงพอใจในความสวยงามของรากเทียมโดยทั่วไปในระดับสูง คิดเป็นร้อยละ 85.9 โดยเฉพาะในเรื่องของสี และรูปร่างของครอบฟัน ในขณะที่ความพึงพอใจต่อความกลมกลืนของขอบเหงือกบริเวณรากเทียมนั้นอยู่ในระดับค่อนข้างต่ำ คิดเป็นร้อยละ 66.6 ความพอใจของผู้ป่วยที่มีต่อรากเทียมในแง่ของการดำเนินชีวิตโดยทั่วไปอยู่ในระดับสูง ยกเว้นในเรื่องของความสบายขณะกัดหรือเคี้ยวอาหารด้วยรากเทียม ซึ่งมีระดับค่อนข้างต่ำ คิดเป็นร้อยละ 70.1 ในแง่ของความสวยงาม พบว่าค่าคะแนนวิซวลอะแนลลิซกสเกลที่ได้จากการประเมินโดยผู้ป่วยและทันตแพทย์นั้นไม่มีความสัมพันธ์กันทางสถิติ โดยที่ระดับความพึงพอใจของทันตแพทย์จะมีค่าต่ำกว่าผู้ป่วยอย่างมีนัยสำคัญในทุกๆ ตัวแปร ($p < 0.05$) นอกจากนี้ยังพบว่าการมีขอบเหงือกกร่นบริเวณรากเทียมไม่ส่งผลต่อการให้คะแนนความพึงพอใจของผู้ป่วยในทุกๆ ตัวแปรที่เกี่ยวข้องกับความสวยงาม ในขณะที่ลักษณะดังกล่าวมีอิทธิพลต่อระดับความพึงพอใจของทันตแพทย์อย่างมีนัยสำคัญ โดยเฉพาะกับทันตแพทย์ในสาขาปริทันตวิทยา

สรุป ผู้ป่วยมีความพึงพอใจในระดับสูงต่อผลการรักษาด้วยรากเทียมบริเวณฟันหน้าบน โดยเมื่อประเมินผลการรักษาในเรื่องของความสวยงาม ทันตแพทย์ให้ความพึงพอใจในระดับที่ต่ำกว่าผู้ป่วย และการมีขอบเหงือกกร่นทางด้านใบหน้าบริเวณรากเทียม ซึ่งเป็นสิ่งที่ทันตแพทย์ให้ความสำคัญและมีอิทธิพลต่อระดับความพึงพอใจมากที่สุด กลับไม่ใช่ปัจจัยที่ส่งผลกระทบต่อระดับความพึงพอใจในผลการรักษาสำหรับผู้ป่วย

(จ. ทันต. จุฬาฯ 2553;33:1-14)

คำสำคัญ: ความพึงพอใจของผู้ป่วย; ความสวยงาม; รากเทียม; วิซวลอะแนลลิซกสเกล; เหงือกกร่น
