



Original Article

บ ท วิ ท ย ำ ก ำ ร

The relationship between vertical and horizontal dimensions of interproximal embrasure and the presence of interdental papilla in maxillary anterior teeth

Suphot Tamsailom D.D.S., M.Sc., Diplome, Thai Board of Periodontology¹

Thanaporn Torsricharoen²

Benjaporn Thanaratikul²

¹Department of Periodontology, Faculty of Dentistry, Chulalongkorn University

²Dental student, Faculty of Dentistry, Chulalongkorn University

Abstracts

Objective This study aimed to determine the relationships between the vertical and horizontal dimensions of interproximal embrasure and the presence of interdental papilla in the maxillary anterior teeth of healthy periodontal young adults.

Materials and methods One hundred and thirty-three interproximal sites of maxillary anterior teeth of 31 third year dental students of the Faculty of Dentistry, Chulalongkorn University who had healthy periodontal status, ages between 19–21 years, were examined. The presence or absence of the interdental papilla was clinically determined. Periapical radiographs were taken on each subject using individual plastic stent with 3.17 mm metal ball for reference and then were scanned to digital images. The vertical and horizontal distances including: vertical distance from contact point to crest of bone (A1); vertical distance from crest of bone to CEJ (A2); horizontal distance between adjacent CEJs (B), were measured with analyzing program and then statistically analyzed using Chi-square, Spearman's correlation, Independent T-test and Mann-Whitney U test.

Results The presence or absence of interdental papilla was correlated with A1 and B ($p < 0.05$), whereas no correlation was found with A2 ($p > 0.05$). In the presence of interdental papilla group, the mean A1 and B were 4.33 ± 0.70 mm and 1.49 ± 0.43 mm, respectively.

Conclusion This study demonstrates the significance of vertical and horizontal dimensions of interproximal embrasure to the presence of interdental papilla.

(CU Dent J. 2010;33:163-72)

Key words: *alveolar bone; interdental papilla; interproximal embrasure; maxillary anterior teeth*

Introduction

The interdental area comprises the contact area, interproximal embrasure, and interproximal dentogingival complex.¹ In normal, healthy dentition, the buccal and lingual/palatal components of interdental papilla are joined in the col area. The shape of the papilla is, therefore, determined by the shape of contact area between adjacent teeth.² The absence of interdental papilla causes open cervical embrasure which is usually associated with food retention. If this problem occurs in the maxillary anterior teeth, esthetic impairment and phonetic problems may become the major concerns of the patient.^{3,4} The recession of interdental papilla, which reflects “black triangle” in the proximal area of maxillary anterior teeth, is commonly found in periodontitis patient, particularly after periodontal treatment. Although the papilla tissue was found to reform to the original height of 3.2–4.3 mm,^{5,6} the apical level of crestal bone due to irreversible periodontal destruction has never rebounded. So far, there is no predictable periodontal management to restore the loss interdental papilla. The combine treatments between periodontics, orthodontics and restorative dentistry may help improve this black triangle by reshaping the interproximal embrasure.⁷

The relationship between the components of interproximal or gingival embrasure and the presence of interdental papilla has been studied by several groups. From Tarnow et al.,³ when the distance between the contact point and the crest of bone was 5 mm or less, the complete papilla fill of the interproximal embrasure was present almost 100% of the time. For every 1 mm greater than 5 mm, the chance of complete papilla fill was progressively reduced by 50%. The papillae were typically absent when the distance was 7 mm or more. However, the measurement of this study included both anterior and posterior teeth of maxilla and mandible which made the mean value of the distance not exactly represent the esthetic zone.

Very few studies have been conducted to find out the mean values of the interproximal dimensions and related factors of the unesthetic black triangle in upper anterior teeth.^{8–11} Most of previous reports carried out in adult patients with wide age range which might include patients who experienced periodontal destruction or other bone resorption associated factors. From the study which had been done in groups of adult orthodontic patients, revealed that age, duration of active orthodontic treatment and crown morphology were associated with open gingival embrasure.¹² In patients over 20 years of age were more frequently found open gingival embrasures than in younger patients.¹³ The presence or absence of interdental papilla found in this age range may explain the significance of the interproximal embrasure dimensions better than in older age range due to the crestal bone level still close to normal. By using the non-invasive radiographic method, the present study was performed to determine the vertical and horizontal dimensions of the interproximal embrasure of maxillary anterior teeth and their relationships to the presence or absence of interdental papilla in young adults.

Materials and Methods

This study was approved by the Ethics Committee of the Faculty of Dentistry, Chulalongkorn University, number 48/2006. A total of 155 interproximal sites of maxillary anterior teeth in 31 subjects of third-year dental students of the Faculty of Dentistry, Chulalongkorn University (8 males, 23 females, aged range 19–21 year-old) were examined. One hundred and thirty-three sites were recruited into the study with the inclusion criteria: having 6 maxillary anterior teeth without open contacts or malpositions; no history of periodontitis; Plaque and Gingival Index¹⁴ of 0–1; and no attrition or abrasion nor any artificial crown or restoration. The presence of the interdental papilla was determined clinically. If no space was visible apical to

the contact area, the papilla was recorded as being present without papilla recession. If there was visible space apical to the contact area, the papilla was recorded as being absent. An individual plastic stent was made with metal balls diameter 3.17 mm for radiographic measurement references (Fig. 1A). Periapical radiographic films were taken using paralleling technique with XCP film holder (Rinn Corporation, Elgin, IL, USA) at 60 KVP 10 mA 1 sec. Each film was then processed with DENT-X 810 Plus (Dent-X, Elmsford, NY, USA) for 4.5 min and then was scanned to digital images at 600 ppi. The distance from the most apical contact area to the crest of bone was measured with analyzing program (Image Pro Plus version 4.5; MediaCybernetics, Silver Spring, MD, USA) using the metal ball for calibration. The measurements included: A1; the vertical distance from the contact point to the crest of bone, A2; the vertical distance from the crest of bone to CEJs, and B; the horizontal distance between the adjacent CEJs (Fig. 1B). The crest of bone was defined as the most coronal level of the alveolar bone. In case of the indistinct alveolar crest shown as a thick gray line in the x-ray film, the crest of bone was then determined from the center of the gray line. In the measurements of A2 and B, if the

adjacent CEJs were not in the same horizontal plane, the imaginary line between the adjacent CEJs levels was then used for the measurement. The clinical examination was done by an experienced periodontist, while the image analyzing was taken by other two investigators who did not know the information of the presence or absence of interdental papilla. The inter-examiner reliability of the two investigators was acceptable ($\kappa = 0.88$).

Statistical analysis

To evaluate the differences in the dimensions of the interproximal area, the measurements of A1 was divided into 4 categories (≤ 4.0 , 4.01–5.00, 5.01–6.00, > 6.0), while A2 and B were divided into 5 categories (≤ 0.80 , 0.81–1.20, 1.21–1.60, 1.60–2.0, > 2.0 , and ≤ 1.0 , 1.01–1.50, 1.51–2.00, 2.01–2.50, > 2.50 , respectively). The Chi-square test was used to find the relationships of the measurements and the presence of interdental papilla. The Spearman's correlation was used to assess the direction of the relationship. To compare the vertical and horizontal dimensions between the present and absent papilla groups, the Independent T-test was used for A2 and B, and the Mann-Whitney

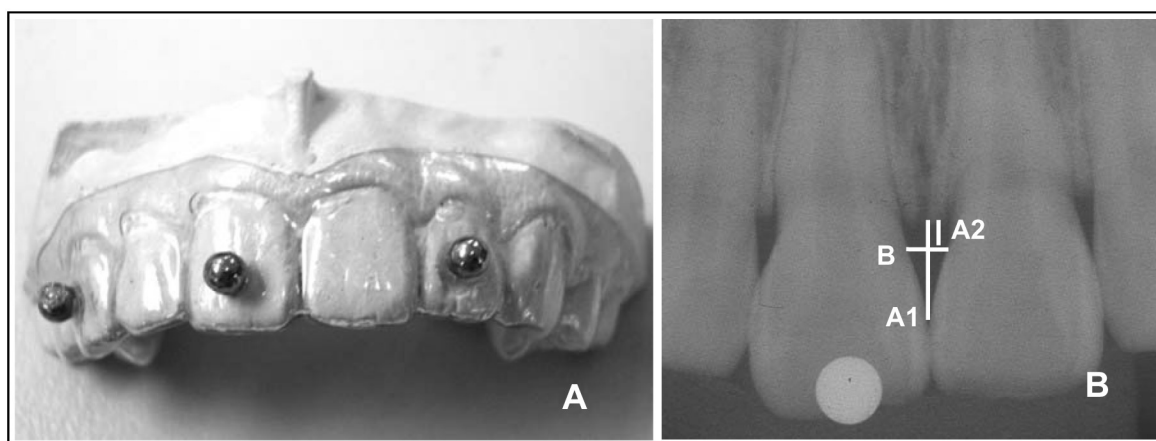


Fig. 1 A. The plastic stent with the metal balls diameter 3.17 mm; B. Radiographic image of maxillary anterior teeth; A1 = the vertical distance from the contact point to the crest of bone, A2 = the vertical distance from the crest of bone to CEJ, B = the horizontal distance between the adjacent CEJs.

U test was used for A1. Statistical analysis was conducted using SPSS® version 13.0 (SPSS®, Inc, Chicago, IL, USA). The level of significance was set at $p < 0.05$.

Results

From 31 subjects (8 males, 23 females; age 19-21 year-old), 133 interproximal sites met the inclusion criteria and were measured by radiographic method. When the distances between the contact point and the bone crest (A1) were ≤ 4.00 , 4.01-5.00, 5.01-6.00 and > 6.00 mm, the percentage of papilla presence were 91.7, 85.9, 60.0 and 16.7, respectively (Table 1). Considering A1 at 5.00 mm or less, the presence of interdental papilla was found in 94 of 107 sites, or 87.9% of the time. A1 showed significant relationship with the presence of interdental papilla ($p = 0.000$). As A1 increased, the percentage of papilla presence decreased ($r = -0.340$, $p = 0.000$). When comparing A1 between the present papilla group (4.33 ± 0.70 mm) and in the absent papilla group (5.20 ± 1.22 mm), they showed statistically significant difference ($p = 0.000$)

(Table 4). The distances from CEJ level to bone crest (A2) was not related to the presence of interdental papilla ($p = 0.262$) (Table 2), and showed no statistically significant difference ($p = 0.567$) between the present and absent papilla groups (1.10 ± 0.28 mm and 1.14 ± 0.24 mm, respectively) (Table 4). The distances between adjacent CEJs (B) showed significant relationship with the presence of interdental papilla ($p = 0.016$) (Table 3). As B increased, the percentage of papilla presence decreased ($r = -0.295$, $p = 0.001$). When B were ≤ 1.50 mm, ≤ 2.00 mm, and ≤ 2.50 mm, the presence of interdental papilla were 91.8%, 83.9% and 81.3% of the time, respectively, while B was ≥ 2.50 mm, the presence of interdental papilla was decreased to 50% of the time. Considering in the absent papilla group, 21 of 26 sites (80.8%) had B greater than 1.50 mm. When comparing B between the present (1.49 ± 0.43 mm) and absent papilla groups (1.83 ± 0.42 mm), they showed statistically significant difference ($p < 0.05$) (Table 4). As far as the group of present interdental papilla was concerned, the mean value of A1 was 4.33 ± 0.70 mm and B was 1.49 ± 0.43 mm (Table 4).

Table 1. The presence or absence of interdental papilla and the vertical distance from the contact point to the crest of bone (A1).

A1 (mm)	Interdental papilla (N=133)		p-value [†]
	Presence	Absence	
≤ 4.00	33 (91.7%)	3 (8.3%)	$p = 0.000$
4.01-5.00	61 (85.9%)	10 (14.1%)	
5.01-6.00	12 (60.0%)	8 (40.0%)	
≥ 6.01	1 (16.7%)	5 (83.3%)	
Total	107 (80.5%)	26 (19.5%)	

[†]Chi-square test is significant at $\alpha = 0.05$

A1: the vertical distance from the contact point to the crest of bone

Table 2. The presence or absence of interdental papilla and the vertical distance from the crest of bone to CEJ (A2).

A2 (mm)	Interdental papilla (N=133)		p-value
	Presence	Absence	
≤ 0.80	16 (88.9%)	2 (11.1%)	p = 0.262
0.81-1.20	47 (75.8%)	15 (24.2%)	
1.21-1.60	42 (84.0%)	8 (16.0%)	
1.61-2.00	1 (50.0%)	1 (50.0%)	
≥ 2.01	1 (100.0%)	0 (0.0%)	
Total	107 (80.5%)	26 (19.5%)	

A2: the vertical distance from the crest of bone to CEJ

Table 3. The presence or absence of interdental papilla and the horizontal distance between the adjacent CEJs (B).

B (mm)	Interdental papilla (N=133)		p-value [†]
	Presence	Absence	
≤ 1.00	12 (100%)	0 (0%)	p = 0.016
1.01-1.50	44 (89.8%)	5 (10.2%)	
1.51-2.00	38 (74.5%)	13 (25.5%)	
2.01-2.50	11 (64.7%)	6 (35.3%)	
≥ 2.51	2 (50.0%)	2 (50.0%)	
Total	107 (80.5%)	26 (19.5%)	

[†]Chi-square test is significant at $\alpha = 0.05$

B: the horizontal distance between the adjacent CEJs

Table 4. Mean distances of A1, A2 and B and the presence or absence of interdental papilla.

Vertical and horizontal dimensions	Interdental papilla (N=133)		p-value
	Presence (N=107) (mean ± SD) (mm)	Absence (N=26) (mean ± SD) (mm)	
A1	4.33 ± 0.70	5.20 ± 1.22	0.000*
A2	1.10 ± 0.28	1.14 ± 0.24	0.567
B	1.49 ± 0.43	1.83 ± 0.42	0.000**

*Mann-Whitney U Test is significant at $\alpha = 0.05$

**Independent T-test is significant at $\alpha = 0.05$

A1: the vertical distance from the contact point to the crest of bone

A2: the vertical distance from the crest of bone to CEJ

B: the horizontal distance between the adjacent CEJs

Discussion

The present study modified the radiographic method to measure the vertical and horizontal distances of the interproximal embrasure, instead of using the direct measurement by bone sounding under local anesthesia. Lee et al. introduced the non-invasive radiographic method to investigate the papilla length in relation to the crestal bone to decrease the patient discomfort.¹¹ They found that this method has high correlation with the direct measurement. The relationship between the components of interproximal embrasure of maxillary anterior teeth and the presence or absence of interdental papilla have been reported.⁸⁻¹¹ However, those studies were done in wide age-range groups. In the present study, we focused on maxillary anterior teeth of young adult age-ranged 19-21 years-old, who had healthy periodontal status and no history of periodontal destruction. These could decrease a major etiologic factor affected to alveolar bone level, which related to the presence or absence of interdental papilla. The alveolar bone level in this subject group should be close to the normal level. This confirmed by

the result in this study. The mean distance of alveolar crest to CEJ of subjects (A2) was 1.11 ± 0.17 mm, which was comparable to the average of normal crestal bone level 1.08 mm from CEJ in young adults.¹⁵ A2 also showed no relationship with the presence or absence of interdental papilla and no difference between the two groups. Considering the distance between contact point to the crest of bone (A1) at up to 5 mm, the results showed that approximately 87.9% of interdental papilla were present, which was slightly less percentage than in the previous study.³ When the distance increased to 6 mm or greater, a significantly increased percentage of absent interdental papilla was observed. When the distance between adjacent teeth at CEJ level (B) was concerned, this study demonstrated the influence of B on the presence or absence of interdental papilla. As the distance between CEJs of adjacent teeth was increased, there was a tendency to increase the possibility of absent interdental papilla. When B was 1.5 mm or less, approximately 92% of present interdental papillae were found. This result supported the finding of Chang et al., which reported

the significant chance of occurrence of central papilla recession in wide interdental width at CEJ level between adjacent maxillary central incisors.⁷

The study of Martegani et al. suggested that when the interradicular distance at CEJ level was more than 2.4 mm, the influence of the distance between contact point to the crest of bone has lost on the presence or absence of the interdental papilla.¹⁰ Although we did not investigate this relationship in the present study, we found that as B was 2.50 mm or greater, the chance to have interdental papilla presence or absence were similar. However, most of the sites in the absence of interdental papilla group (80.8%) were found when B was greater than 1.50 mm.

Several surgical approaches have been reported to restore the soft tissue in area of the unesthetic “black triangle” of maxillary anterior teeth.¹⁷⁻²³ However, they failed to achieve long-term stability and predictability mainly because of the insufficient blood supply in the interdental area.²⁴ For the management of this deficient interdental papilla, the non-surgical methods may help to reduce this interproximal space by decreasing the gingival embrasure, which is best achieved with restorative or orthodontic treatment.^{7,15} The restorative materials are used to alter the mesial contours of adjacent teeth and move the contact point more apically.²⁴ Orthodontic treatment in conjunction with tooth stripping can be performed to reduce the volume of the gingival embrasure.¹⁶ Both restorative and orthodontic treatments result in apical positioning of the contact point and also reduce the adjacent CEJ distance. It is interesting that, to close the “black triangle”, we need to decrease the vertical component from contact point to the crest of bone and create an optimal horizontal distance between adjacent teeth.

Conclusion

This study demonstrates the significant relationship of the vertical and horizontal dimensions of the gingival

embrasure on the presence or absence of interdental papilla, however, other components and related factors should be further investigated. As far as the presence of interdental papilla is concerned, the mean value of the distance from contact point to the crest of bone is 4.33 mm, and the distance between adjacent CEJs is 1.49 mm.

Acknowledgement

This study was supported by the Faculty of Dentistry Research Fund, Chulalongkorn University, Bangkok, Thailand. The authors would like to thank Dr. Ketsuda Thovanich, Dental Implant Unit, and Dr. Vannaporn Chuenchompoonut, Department of Radiology, for their technical supports; Assoc.Prof. Chanchai Hosanguan and Assist.Prof. Dr. Patita Bhuridej, Department of Community Dentistry, for their advices in statistical analyses.

References

1. Takei HH. The interdental space. *Dent Clin North Am.* 1980;24:169-76.
2. Lindhe J, Wennström J, Berglundh T. Chapter 3 The mucosa at teeth and implant. In: Lindhe J, Lang NP, Karring T, editors. *Clinical Periodontology and Implant Dentistry*, vol. 1, 5th ed. Oxford: The Blackwell Publishing Company, 2008:69-85.
3. Tarnow DP, Magner AW, Fletcher P. The effect of the distance from the contact point to the crest of bone on the presence or absence of the interproximal dental papilla. *J Periodontol.* 1992;63:995-6.
4. Prato GP, Rotundo R, Cortellini P, Tinti C, Azzi R. Interdental papilla management: a review and classification of the therapeutic approaches. *Int J Periodontics Restorative Dent.* 2004;24:246-55.
5. van der Velden U. Regeneration of the interdental soft tissues following denudation procedures. *J Clin Periodontol.* 1982;9:455-9.

6. Pontoriero R, Carnevale G. Surgical crown lengthening: a 12-month clinical wound healing study. *J Periodontol.* 2001;72:841-8.
7. Miller PD, Allen EP. The development of periodontal plastic surgery. *Periodontol* 2000. 1996;11:7-17.
8. Kurth JR, Kokich VG. Open gingival embrasures after orthodontic treatment in adults: prevalence and etiology. *Am J Orthod Dentofacial Orthop.* 2001;120:116-23.
9. Chang LC. The association between embrasure morphology and central papilla recession. *J Clin Periodontol.* 2007;34:432-6.
10. Martegani P, Silvestri M, Mascarello F, Scipioni T, Ghezzi C, Rota C, et al. Morphometric study of the interproximal unit in the esthetic region to correlate anatomic variables affecting the aspect of soft tissue embrasure space. *J Periodontol.* 2007; 78:2260-5.
11. Lee DW, Kim CK, Park KH, Cho KS, Moon IS. Non-invasive method to measure the length of soft tissue from the top of the papilla to the crestal bone. *J Periodontol.* 2005;76:1311-4.
12. Ikeda T, Yamaguchi M, Meguro D, Kasai K. Prediction and causes of open gingival embrasure spaces between the mandibular central incisors following orthodontic treatment. *Aust Orthod J.* 2004;20:87-92.
13. Ko-Kimura N, Kimura-Hayashi M, Yamaguchi M, Ikeda T, Meguro D, Kanekawa M, et al. Some factors associated with open gingival embrasures following orthodontic treatment. *Aust Orthod J.* 2003;19:19-24.
14. Loe H, Silness J. Periodontal disease in pregnancy. I. prevalence and severity. *Acta Odontol Scand.* 1963;21:533-51.
15. Garguilo AW, Wentz FM, Orban B. Dimensions and relations of the dentogingival junction in humans. *J Periodontol.* 1961;32:261-7.
16. Zetu L, Wang HL. Management of inter-dental/ inter-implant papilla. *J Clin Periodontol.* 2005;32: 831-9.
17. Beagle JR. Surgical reconstruction of the interdental papilla: case report. *Int J Periodontics Restorative Dent.* 1992;12:145-51.
18. Han TJ, Takei HH. Progress in gingival papilla reconstruction. *Periodontol* 2000. 1996;11:65-8.
19. Azzi R, Etienne D, Carranza F. Surgical reconstruction of the interdental papilla. *Int J Periodontics Restorative Dent.* 1998;18:467-73.
20. Azzi R, Etienne D, Sauvan JL, Miller PD. Root coverage and papilla reconstruction in class IV recession: a case report. *Int J Periodontics Restorative Dent.* 1999;19:449-55.
21. Azzi R, Takei HH, Etienne D, Carranza F. Root coverage and papilla reconstruction using autogenous osseous and connective tissue grafts. *Int J Periodontics Restorative Dent.* 2001;21:141-7.
22. Nemcovsky CE. Interproximal papilla augmentation procedure: a novel surgical approach and clinical evaluation of 10 consecutive procedures. *Int J Periodontics Restorative Dent.* 2001;21:553-9.
23. Nordland WP, Sandhu HS. Microsurgical technique for augmentation of the interdental papilla: three case reports. *Int J Periodontics Restorative Dent.* 2008;28:543-9.
24. Blatz MB, Hurzeler MB, Strub JR. Reconstruction of the lost interproximal papilla-presentation of surgical and nonsurgical approaches. *Int J Periodontics Restorative Dent.* 1999;19:395-406.

ความสัมพันธ์ระหว่างระยะแนวตั้งและ แนวราบของช่องระหว่างฟันกับการปรากฏ ของเหงือกสามเหลี่ยมในฟันหน้าบน

สุพจน์ ตามสายลม ท.บ., วท.ม., อ.ท.(ปริทันตวิทยา)¹

ธนาภรณ์ ต่อศรีเจริญ²

เบญจพร ธนรติกุล²

¹ภาควิชาปริทันตวิทยา คณะทันตแพทยศาสตร์ จุฬาลงกรณ์มหาวิทยาลัย

²นิติตรรกวิทยาบัณฑิต คณะทันตแพทยศาสตร์ จุฬาลงกรณ์มหาวิทยาลัย

บทคัดย่อ

วัตถุประสงค์ เพื่อศึกษาความสัมพันธ์ระหว่างระยะแนวตั้งและแนวราบของช่องระหว่างฟันกับการปรากฏของเหงือกสามเหลี่ยมในฟันหน้าบนในกลุ่มผู้ใหญ่อายุน้อยที่มีสภาวะปริทันต์ดี

วัสดุและวิธีการ ศึกษาช่องระหว่างฟันหน้าบน จำนวน 133 ตำแหน่ง ของนิสิตทันตแพทย์ชั้นปีที่ 3 คณะทันตแพทยศาสตร์ จุฬาลงกรณ์มหาวิทยาลัย ที่มีสภาวะปริทันต์ดี จำนวน 31 คน อายุระหว่าง 19-21 ปี โดยตรวจทางคลินิกเพื่อพิจารณาเหงือกสามเหลี่ยมว่าเต็มหรือไม่เต็มช่องระหว่างฟัน ทำการถ่ายภาพรังสีโดยใช้เฟืองฟันพลาสติกที่ติดลูกเหล็กขนาดเส้นผ่านศูนย์กลาง 3.17 มม. อยู่เพื่อใช้อ้างอิงในการวัด จากนั้นแปลงภาพรังสีเป็นภาพดิจิทัล เพื่อวัดระยะต่างๆ จากโปรแกรมวิเคราะห์ภาพ ได้แก่ ระยะจากได้จุดสัมผัสระหว่างซี่ฟันถึงสันกระดูกเบ้าฟัน (เอ1) ระยะจากกระดูกเบ้าฟันถึงระดับรอยต่อระหว่างเคลือบฟันและเคลือบรากฟัน (เอ2) ระยะแนวราบระหว่างฟันที่รอยต่อระหว่างเคลือบฟันและเคลือบรากฟัน (บี) จากนั้นวิเคราะห์ด้วยสถิติโคสแควร์ สถิติสหสัมพันธ์เพียร์แมน อินดีเพนเดนซ์ ที-เทสต์ และแมนนิตนีย์-ยู

ผลการศึกษา การปรากฏของเหงือกสามเหลี่ยมเต็มช่องว่างระหว่างฟันสัมพันธ์กับ เอ1 และบี อย่างมีนัยสำคัญทางสถิติ ($p < 0.05$) แต่ไม่สัมพันธ์กับ เอ2 ($p > 0.05$) ในกลุ่มที่มีเหงือกสามเหลี่ยมเต็มช่องว่างระหว่างฟัน ค่าเฉลี่ยของ เอ1 และบี มีค่า 4.33 ± 0.70 มม. และ 1.49 ± 0.43 มม. ตามลำดับ

สรุป การศึกษานี้แสดงถึงความสำคัญของระยะแนวตั้งและแนวราบของช่องระหว่างฟันต่อการปรากฏของเหงือกสามเหลี่ยมในฟันหน้าบน

(จ. ทันต. จุฬาฯ 2553;33:163-72)

คำสำคัญ: กระดูกเบ้าฟัน; ช่องว่างระหว่างฟัน; ฟันหน้าบน; เหงือกสามเหลี่ยมระหว่างฟัน