



Acemannan in orabase did not cause allergy to skin and oral mucosa in a short-term exposure

Suwimon Jettanacheawchankit, D.D.S., Ph.D.¹

Polakit Sangvanich, B.Sc, M.S., Ph.D.²

Pasutha Thunayakitpibal, D.D.S., Ph.D.³

¹Department of Oral Biology, Faculty of Dentistry, Naresuan University.

²Department of Chemistry, Faculty of Science, Chulalongkorn University.

³Research Unit of Herbal Medicine, Biomaterial, and Material for Dental Treatment, Department of Anatomy, Faculty of Dentistry, Chulalongkorn University.

Abstract

Objective To evaluate the allergic reaction of skin and oral mucosa to acemannan orabase in a short-term observation.

Materials and methods Forty-eight healthy subjects (24 females and 24 males) participated in this study. The closed patch test was used to observe and compare the skin reaction after exposure to 0.5% acemannan orabase and plain orabase (gelatin, pectin, carboxymethylcellulose sodium, liquid paraffin, and polyethylene glycol) for 48 and 72 hours. For the oral mucosal reaction, the repeated oral application test was performed. The participants were instructed to apply the 0.5% acemannan orabase onto their lower labial mucosa 3 times per day after meals for 7 consecutive days. The area was interpreted according to the International Contact Dermatitis Research Group. The data were collected and the tissue reaction was described.

Results Neither dermal reaction nor oral mucosal reaction to acemannan orabase were detected after 3 and 7 days of application, respectively.

Conclusion Acemannan orabase did not cause allergy to the skin and oral mucosa in a short term observation.

(CU Dent J. 2016;39:1-8)

Key words: *Acemannan; AceAloe vera; orabase; patch test; repeated oral application test.*

Correspondence: Pasutha Thunayakitpibal, pthunyak@yahoo.com

Introduction

Aphthous ulceration, a common ulcer in the oral cavity, is characterized by recurrent round or oval ulcers with well-circumscribed red halo margins (Messadi and Younai, 2010). These ulcers cause discomfort and pain and reduce a patient's quality of life. Aphthous ulcers are clinically classified into 3 types: minor aphthous, major aphthous, and herpetiform ulceration (Scully and Felix, 2005). The precise etiology of these lesions is unclear (Scully and Felix, 2005; Messadi and Younai, 2010). Currently, topical corticosteroids are typically used to control the symptoms, supplemented with local anesthetics and antimicrobial agents (Scully and Felix, 2005; Messadi and Younai, 2010). However, prolonged or repeated corticosteroid use increases the risk of intraoral fungal infection and adrenal suppression (Savage and McCullough, 2005; Scully and Felix, 2005). Therefore, there is increased investigation into the development of safe curative herbal medicines with a suitable usage form.

Aloe vera is a perineal succulent plant that retains water in its leaves. *Aloe vera* gel from its inner leaves has been used as an ancient cosmeceutical and pharmaceutical agent on the skin (Sharrif Moghaddasi and Verma, 2011). This medicinal herb is well-known to induce burn- and gastric ulcer-healing (Mahattanadul, 1996; Maethaisong, et al., 2007). Acemannan, a β -(1,4)-polymannose extracted from *Aloe vera*, has been reported to have *in vitro* and *in vivo* biocompatibility and potency in oral wound healing (Jettanacheawchankit, et al., 2009; Jittapiromsak, et al., 2010; Bhalang, et al., 2013; Boonyagul, et al., 2014; Chantarawatit, et al., 2014). Acemannan stimulated gingival fibroblast proliferation and growth factor secretion (Jettanacheawchankit, et al., 2009). Patients with oral aphthous ulcers treated with an acemannan gel formulation for 7 days exhibited healing comparable to those treated with triamcinolone acetonide (Bhalang, et al., 2013).

From the data obtained from patient questionnaires and interviews, the main drawback of this gel formulation was its high hydrophilicity. To improve acemannan's oral mucosal adhesiveness, an acemannan in orabase formulation has been developed.

Orabase, one of the conventional mucoadhesive paste, is comprised of pectin, gelatin, carboxymethyl-cellulose, polyethylene resin, and mineral oil gel base (Taweessup, 1998; Nagalaxmi, et al., 2014). It was classified as hydrophobic gel, dental paste, or ointment due to the high portion of liquid oil base in its constituents. In dentistry, the orabase is commonly used as a drug carrier of 0.1% triamcinolone acetonide for management of aphthous ulceration (Labib and Aldawsari, 2015). When applied onto the mucosal surface, it can be retained at the site for 15–150 minutes (Nagalaxmi, et al., 2014). Although the orabase formulation has been proven for its biocompatibility, adding new ingredient into the orabase may cause an unexpected chemical substance interaction. Therefore, the orabase with new active ingredient must be examined for safety and clinical adverse effects prior to clinical use (Singh, et al., 2012).

An adverse drug reaction is an unexpected condition caused by a drug used in normal treatment doses. It is commonly manifested as drug allergy or hypersensitivity. Hypersensitivity consists of immediate- and delayed-type which are mediated by immunoglobulin E antibody and cellular immune mechanisms, respectively (Yagiela, et al., 2004; Becker, 2013). Contact allergy occurs when drugs or substances contact tissue and elicit a hypersensitivity reaction on the skin or mucosa that was previously sensitized with the corresponding drug or substance (De Rossi and Greenberg, 1998). The objective of this study was to evaluate the allergic reaction of acemannan in orabase on the skin and oral mucosa over a 3 and 7-day period, respectively.

Materials and methods

Acemannan extraction and characterization

Aloe vera (*Aloe barbadensis* Miller) was obtained from a local herbal supplier in Bangkok, Thailand, and the specimen (No. 051101) was deposited in the Museum of Natural Medicines, Faculty of Pharmaceutical Sciences, Chulalongkorn University, Bangkok, Thailand.

Acemannan was extracted from fresh *Aloe vera* gel by homogenization, centrifugation, and alcohol precipitation as previously described (Jettanacheawchankit, et al., 2009). The monosaccharide composition, structure, and molecular mass of the extracted polysaccharide were analyzed by liquid chromatography, ¹H-NMR, FT-IR, and size-exclusion chromatography, respectively (Tai-Nin Chow, et al., 2005; Jettanacheawchankit, et al., 2009; Chokboribal, et al., 2015). The data obtained confirmed that the polysaccharide was acemannan.

Acemannan in orabase formulation was produced as a previous described with minor modification. The Acemannan in orabase composed of acemannan (0.5%), gelatin (16.1%), pectin (16.1%), carboxymethylcellulose sodium (16.1%), liquid paraffin (38.5%), and polyethylene glycol (12.7%) (Taweessup, 1998; Labib and Aldawsari, 2015).

Clinical procedure

The protocol of this study was approved by the Human Ethical Institutional Review Board, Naresuan University (IRB No. 487/57). The sample size was calculated from a formula $n = Z_{\alpha/2}^2 PQ/d^2$ which $Z_{\alpha/2} = 1.96$, $P = 0.01$ (according to the data from Bhalang, et al., 2013.), $Q = 1 - P = 0.99$, and $d =$ acceptable error = 0.03, respectively. The calculated sample size was 43. Then loss of follow up bias was compensated, the sample size was increased to 48.

Forty-eight healthy subjects (24 females and 24 males) were recruited from Phitsanulok, Thailand. The exclusion criteria were immunocompromised conditions, autoimmune diseases, skin diseases, oral

mucosal diseases, or allergic history to *Aloe vera*. The subjects should not have received any corticosteroids, antihistamines, or immunomodulatory agents 2 weeks before or during the experiment. Participants who were pregnant or breastfeeding were also excluded. The volunteers read and signed inform consent forms prior to the commencement of the study.

The closed patch test was used to observe the skin reaction to acemannan orabase as previously described with some modifications (Wattanakrai, et al., 2007; Bhalang, et al., 2013). Briefly, a chamber test set consisted of 2 chambers (AllergEAZE Clear Patch Test Chambers, SmartPractice, USA) that were loaded with either 0.5% acemannan in orabase or plain orabase (gelatin, pectin, carboxymethylcellulose sodium, and polyethylene resin). Three sets of test chambers were then placed on the left upper back skin of each subject (Fig. 1). After 4 h, one of the three sets was randomly removed, and the skin reaction was interpreted according to the International Contact Dermatitis Research Group (Table 1) (Spiewak, 2008). If there were no signs of irritation or allergy, the remaining sets were continued and interpreted at 48 and 72 hours. The skin area was recorded using a digital camera.

Simultaneously with the skin test, the subjects underwent a repeated oral application test with some modifications to evaluate any mucosal reaction (Nakada, et al., 2000). The participants were instructed to apply 0.1 gram of 0.5% acemannan orabase on their lower labial mucosa 3 times per day after meals for 7 consecutive days. The reaction was initially evaluated 1 hour after the first application. If there were no signs of irritation, inflammation, or lichenoid reaction, the experiment was continued and evaluated again at day 7. If any reactions were observed, the oral mucosal area was photographed by a digital camera.

The demographic data were collected and presented by descriptive statistic (mean \pm standard deviation). The reactions, if any, were described.




Fig. 1 Patch test chambers used in this study (A). The closed patch test performed on the left upper back skin of a representative subject (B).

Table 1 Skin reaction interpretation according to the International Contact Dermatitis Research Group (modified from Spiewak R, 2008)

Skin appearance in tested area	Interpretation
No skin changes	Negative
Faint, non-palpable erythema	Doubtful [§]
Palpable erythema	Weak reaction
Strong infiltrate, numerous papules or vesicles	Strong reaction
Fusing vesicles, bullae or ulceration	Extreme reaction
Inflammation limited to tested area, lack of infiltrate, small petechiae or pustules	Irritant reaction

§ Most studies do not consider this a positive reaction.

Results

The twenty-four male and twenty-four female subjects were 32.7 ± 6.7 and 34.4 ± 5.5 years old, respectively. One subject dropped out of the study for personal reasons. Neither dermal nor oral mucosal reaction to acemannan orabase was detected in any subjects (Fig. 2). Three subjects (one male and two female, 4.167% and 8.696%, respectively) developed faint erythema at the area of skin in contact with the medical adhesive tape at 72 h exposure. The erythema area was confined at the area of medical adhesive tape

around the square area of both loading chambers that contained plain orabase and 0.5% acemannan orabase (Fig. 3A and 4A). In the square area of both plain orabase and 0.5% acemannan orabase loading chambers, small non-homogenous spots of faint erythema were observed (Fig. 3A and 4A). However, all the skin erythema disappeared within 24 hours after removal of the tape (Fig. 3B and 4B). No subjects exhibited oral mucosal reactions after 7 days of acemannan application.

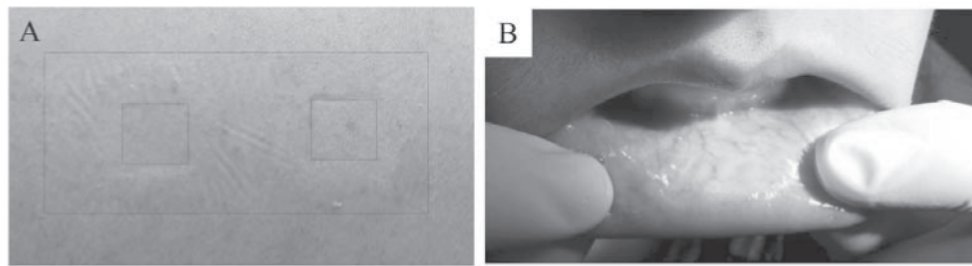


Fig. 2 Photographs of a typical skin area contacted with the medical adhesive and patch test chamber contained plain orabase and 0.5% acemannan orabase for 72 h exposure (A) and typical lower labial mucosa after applied with 0.5% acemannan orabase 3 times per day for 7 consecutive days (B).




Fig. 3 Photographs of a representative male subject who developed faint erythema at the area of skin in contact with the medical adhesive at 72 h exposure (A) and 24 h after removal of the adhesive and chambers (B).

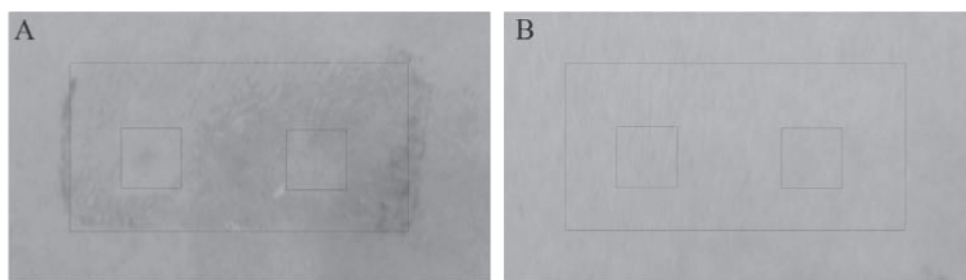


Fig. 4 Photographs of a representative female subject who developed faint erythema at the area of skin in contact with the medical adhesive at 72 h exposure (A) and 24 h after removal of the adhesive and chambers (B).

Discussion

Over the last few decades, herbs have become popular as alternative medicines because of their natural origin. Although herbs have long been used as traditional remedies, investigation of the safety and clinical adverse effects of these natural products and of the product in different vehicles or formulations are required (Singh, et al., 2012). In this study, the effect of acemannan in orabase on contact allergy was assessed using the closed patch test and the repeated

open application test.

The patch test is a reliable, reproducible, and noninvasive approved test for diagnosing contact allergy (Spiewak, 2008). This test has a high specificity with a good positive predictive value that reduces/eliminates the chance of false positives (Pourpak, et al., 2008). In our study, the closed patch test was performed to evaluate the skin reaction to acemannan in orabase. Neither contact allergy nor irritation was detected in the volunteers after skin contact exposure

for 3 consecutive days of exposure, which is consistent with the closed skin patch test of acemannan in gel formulation (Bhalang, et al., 2013).

The faint erythema skin area in three subjects was confined at the area contacted with adhesive tape and around both of the loading chambers that contained plain orabase and 0.5% acemannan orabase. Its appearance was not grainy-liked, papular, and vesicular lesion which is the sign of allergy. Thus, it was not an allergic reaction to the both tested substances, but an irritation reaction to the adhesive tape. The contact irritation is a local inflammation due to local contact with a drug or substance that does not involve an immune mechanism (Issa, et al., 2005).

The skin irritation from the medical adhesive tape was stated due to the residual unpolymerized acrylic monomers (Kanerva, et al., 1997; Tokumura, et al., 2010). In addition, the strong adhesion caused the stripping of corneocytes when removal the adhesive tape has been suggested (Sidi and Hincky, 1957; Tokumura, et al., 2007; Gryson, 2012). The non-homogenous faint erythema in both loading chamber area may be due to the prolonged blocking of hair follicle and sweat gland orifice via the tested substances, and local microorganism activity and modification in that area (Sidi and Hincky, 1957; Gryson, 2012). However, an irritation reaction due to an orabase composition cannot be excluded and further investigations are still required.

From our observation, the patch test is not practical on the moist and movable oral mucosa. Most volunteers felt uncomfortable having a test chamber in their mouths. Therefore, the repeated open application test was performed to evaluate the oral mucosal reaction to acemannan orabase. The advantage of this test is that it simulates the clinical application of acemannan orabase in the oral cavity, and typically is

used to confirm the results obtained from a skin patch test (Nakada, et al., 2000; Villarama and Maibach, 2004). It has been reported that half of the positive patch tests cases were negative in the repeated open application test. This may be because the biological reaction to a substance in an open environment was insufficient to produce clinical signs (Villarama and Maibach, 2004). The concentration of a substance can be diluted by saliva and swallowed, which reduces the possible interactions between allergens and antigen-presenting cells (Rai, et al., 2014). In our study, the signs of oral contact allergy, such as contact allergic stomatitis/cheilitis, lichenoid reaction, fixed drug reaction, and burning mouth, were not detected after 7 days of oral application. It should be noted that the three volunteers who developed the faint erythematous skin area in the patch test did not have any irritation reactions in the repeated open application test. This indicates that the irritation reaction on the skin was due to the adhesive tape, not acemannan orabase. In addition, the skin patch test and the repeated open application test were performed concurrently to investigate the possibility of immediate-or delayed-type hypersensitivity reaction. Investigations into the long term adverse effects or toxicity should be performed to confirm the safety of acemannan orabase.

In conclusion, acemannan in orabase exhibited a non-allergic effect on the skin and oral mucosa after 7 days of application.

Acknowledgements

We thank Professor Dr. Visaka Limwong, Associate Professor Dr. Dolly Methatharathip, and Dr. Kevin A. Tompkins for their valuable suggestions. This work was supported by the Thailand Research Fund, National Research Council of Thailand, and Agricultural Research Development Agency (CRP5705020460). No conflicts of interest exist.

References

- Becker DE. Drug allergies and implications for dental practice. *Anesth Prog.* 2013;60:188-97.
- Bhalang K, Thunyakitpaisal P, Rungsirisatean N. Acemannan, a polysaccharide extracted from aloe vera, is effective in the treatment of oral aphthous ulceration. *J Altern Complement Med.* 2013;19:429-34.
- Boonyagul S, Banlunara W, Sangvanich P, Thunyakitpaisal P. Effect of acemannan, an extracted polysaccharide from aloe vera, on bmscs proliferation, differentiation, extracellular matrix synthesis, mineralization, and bone formation in a tooth extraction model. *Odontology.* 2014;102:310-7.
- Chantarawatit P, Sangvanich P, Banlunara W, Soontornvipart K, Thunyakitpaisal P. Acemannan sponges stimulate alveolar bone, cementum and periodontal ligament regeneration in a canine class ii furcation defect model. *J Periodontal Res.* 2014;49:164-78.
- Chokboribal J, Tachaboonyakiat W, Sangvanich P, Ruangpornvisuti V, Jettanacheawchankit S, Thunyakitpaisal P. Deacetylation affects the physical properties and bioactivity of acemannan, an extracted polysaccharide from aloe vera. *Carbohydrate Polymers.* 2015;133:556-66.
- De Rossi SS, Greenberg MS. Intraoral contact allergy: A literature review and case reports. *J Am Dent Assoc.* 1998;129:1435-41.
- Gryson L. An evolution in medical tapes: From latex to acrylic. *EWMA Journal.* 2012;12:21-4.
- Issa Y, Duxbury AJ, Macfarlane TV, Brunton PA. Oral lichenoid lesions related to dental restorative materials. *Br Dent J.* 2005;198:361-6; discussion 549; quiz 372.
- Jettanacheawchankit S, Sasithanasate S, Sangvanich P, Banlunara W, Thunyakitpaisal P. Acemannan stimulates gingival fibroblast proliferation; expressions of keratinocyte growth factor-1, vascular endothelial growth factor, and type i collagen; and wound healing. *J Pharmacol Sci.* 2009;109:525-31.
- Jittapiromsak N, Sahawat D, Banlunara W, Sangvanich P, Thunyakitpaisal P. Acemannan, an extracted product from *aloe vera*, stimulates dental pulp cell proliferation, differentiation, mineralization, and dentin formation. *Tissue Eng Part A.* 2010;16:1997-2006.
- Kanerva L, Jolanki R, Estlander T. 10 years of patch testing with the (meth)acrylate series. *Contact Dermatitis.* 1997;37:255-8.
- Labib GS, Aldawsari H. Innovation of natural essential oil-loaded orabase for local treatment of oral candidiasis. *Drug Des Devel Ther.* 2015;9:3349-59.
- Maethaisong R, Chaiyakunapruk N, Niruntraporn S, Kongkaew C. The efficacy of aloe vera used for burn wound healing: A systematic review. *Burns.* 2007;33:713-8.
- Mahattanadul S. Antigastric ulcer properties of *aloe vera*. *Songklanakarini J Sci Technol.* 1996;18:49-57.
- Messadi DV, Younai F. Aphthous ulcers. *Dermatol Ther.* 2010;23:281-90.
- Nagalaxmi V, Reddy SS, Jyothi MN, Srikanth K, Palem S, Lalitha C, et al. Oral mucosal drug delivery—an adjunct to the current therapeutic strategies in the dental management of oral diseases: Review. 2014;13:1034-40.
- Nakada T, Hostynek JJ, Maibach HI. Use tests: Roat (repeated open application test)/put (provocative use test): An overview. *Contact Dermatitis.* 2000;43:1-3.
- Pourpak Z, Fazlollahi MR, Fattahi F. Understanding adverse drug reactions and drug allergies: Principles, diagnosis and treatment aspects. *Recent Pat Inflamm Allergy Drug Discov.* 2008;2:24-46.

- Rai R, Dinakar D, Kurian SS, Bindoo YA. Investigation of contact allergy to dental materials by patch testing. *Indian Dermatol Online J.* 2014; 5:282-6.
- Savage NW, McCullough MJ. Topical corticosteroids in dental practice. *Aust Dent J.* 2005;50:S40-4.
- Scully C, Felix DH. Oral medicine-update for the dental practitioner. Aphthous and other common ulcers. *Br Dent J.* 2005;199:259-64.
- Sharrif Moghaddasi M, Verma SK. Aloe vera their chemicals composition and applications: A review. *Int J Biol Med Res.* 2011;2:466-71.
- Sidi E, Hincky M. Allergic sensitization to adhesive tape; experimental study with a hypoallergenic adhesive tape. *J Invest Dermatol.* 1957;29:81-90.
- Singh D, Gupta R, Saraf SA. Herbs-are they safe enough? An overview. *Crit Rev Food Sci Nutr.* 2012;52:876-98.
- Spiewak R. Patch testing for contact allergy and allergic contact dermatitis. *Open Allergy J.* 2008;1:42-51.
- Tai-Nin Chow J, Williamson DA, Yates KM, Goux WJ. Chemical characterization of the immunomodulating polysaccharide of *aloe vera* L. *Carbohydr Res.* 2005;340:1131-42.
- Taweessup W. Dental formulary. Bangkok: CU book, 1998:6-7.
- Tokumura F, Homma T, Tomiya T, Kobayashi Y, Matsuda T. Properties of pressure-sensitive adhesive tapes with soft adhesives to human skin and their mechanism. *Skin Res Technol.* 2007; 13:211-6.
- Tokumura F, Matsui T, Suzuki Y, Sado M, Taniguchi M, Kobayashi I, et al. The potential dermal irritating effect of residual (meth)acrylic monomers in pressure sensitive adhesive tapes. *Drug Chem Toxicol.* 2010;33:1-7.
- Villarama CD, Maibach HI. Correlations of patch test reactivity and the repeated open application test (roat)/provocative use test (put). *Food Chem Toxicol.* 2004;42:1719-25.
- Wattanakrai P, Suwanachote S, Kulkollakarn S, Rajatanavin N. The study of human skin irritation of a novel herbal skin care product and ingredients by human single closed patch testing. *J Med Assoc Thai.* 2007;90:1116-22.
- Yagiela JA, Dowd FJ, Neidle EA. *Pharmacology and therapeutics for dentistry.* 5th ed. St. Louis: Elsevier Mosby, 2004:54-58.